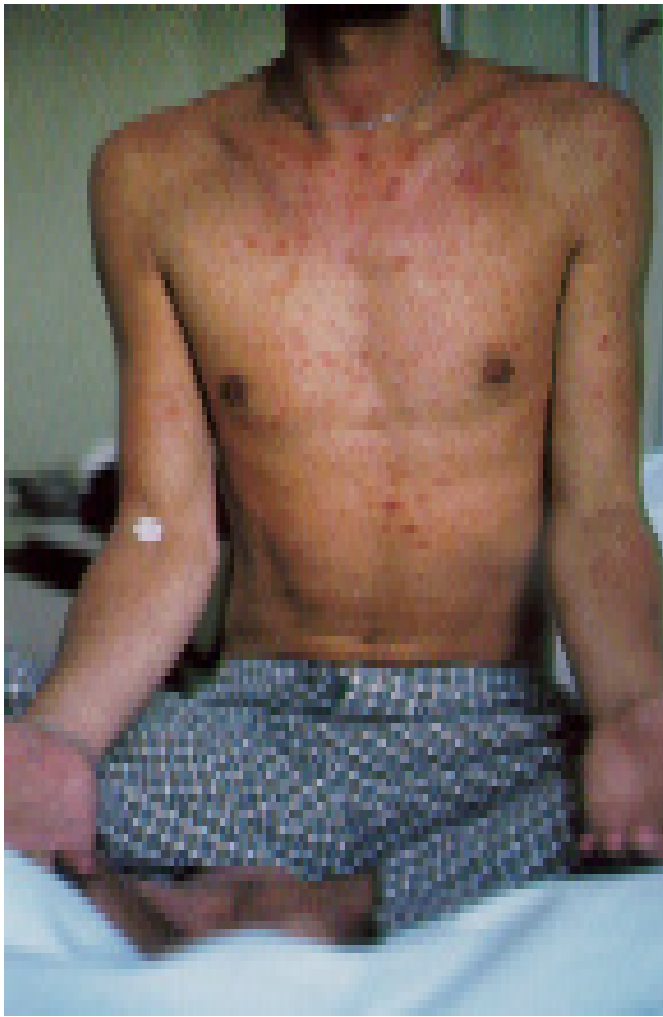
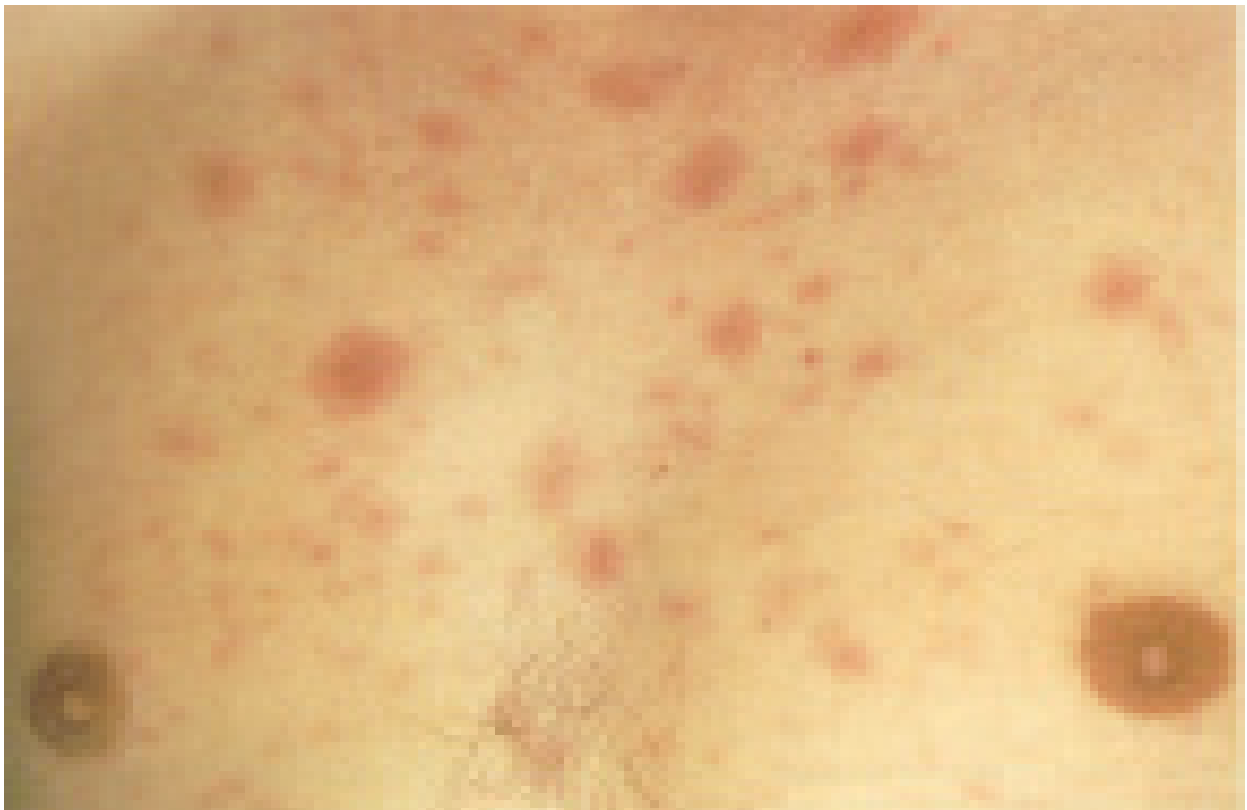
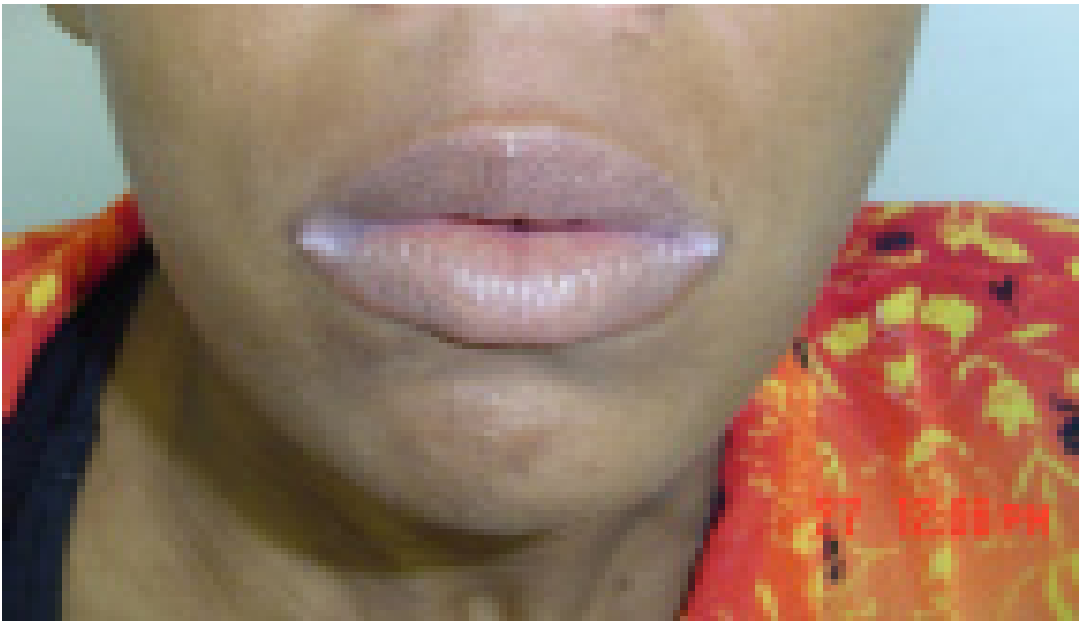


Acute HIV, a/k/a Primary HIV Infection

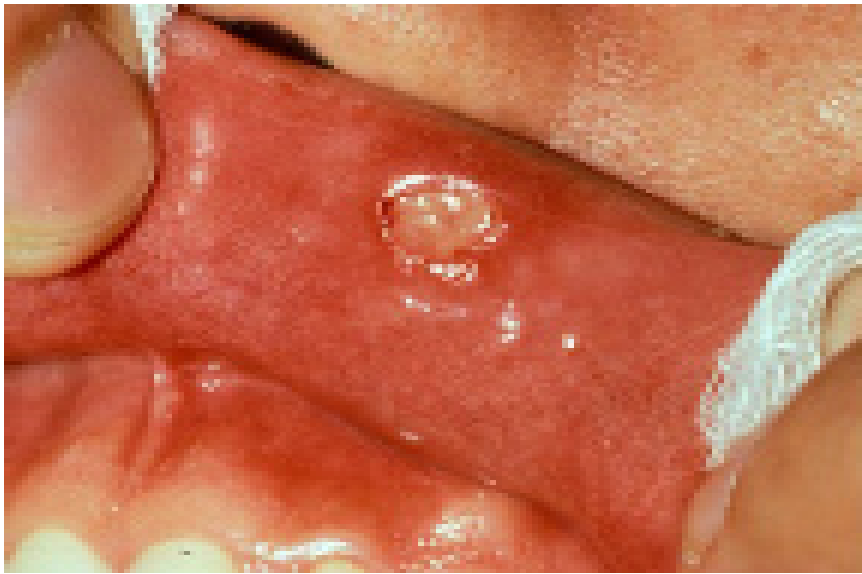




Angular Cheilitis
photo courtesy Jeffrey Edwards, MD

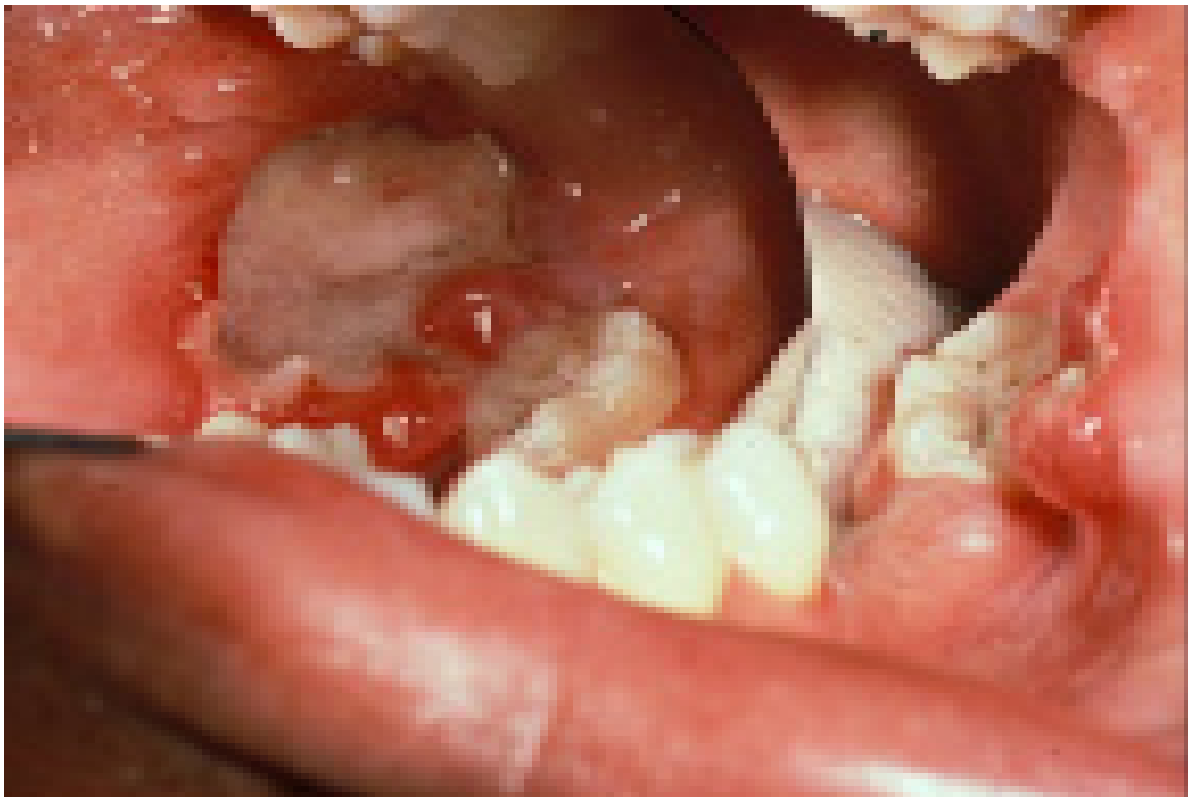Anogenital warts
photo courtesy Jeffrey Edwards, MD

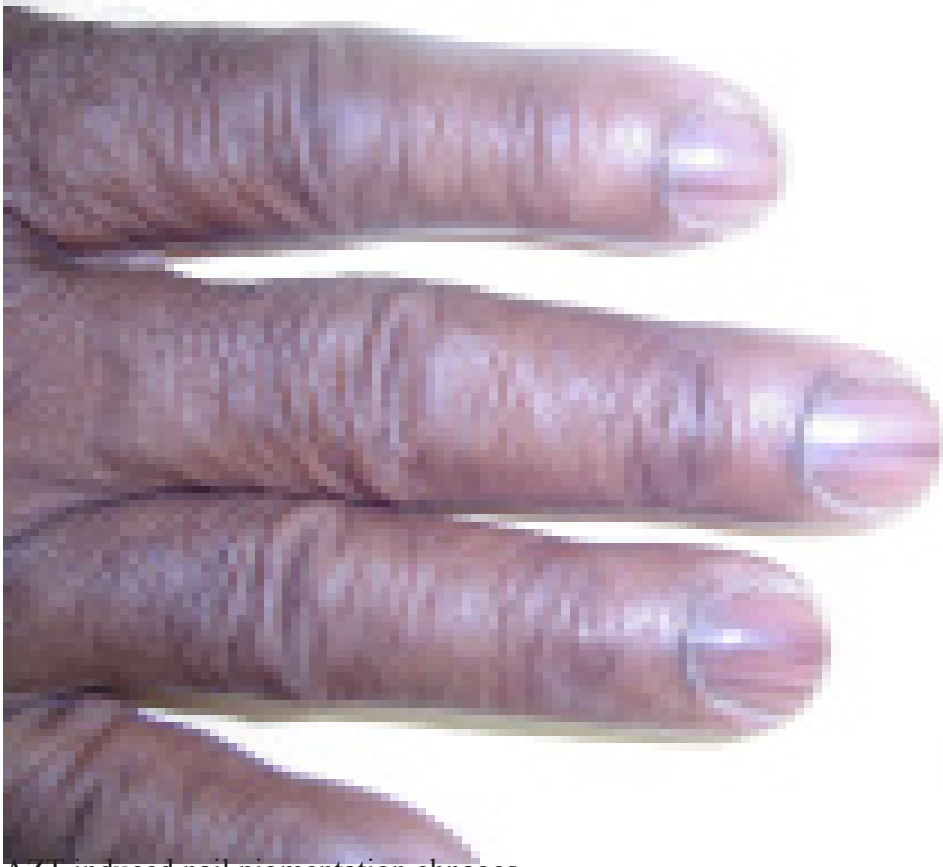



Aphthous Ulcer, a/k/a Aphthous Stomatitis
photo courtesy Mark Schubert, DDS

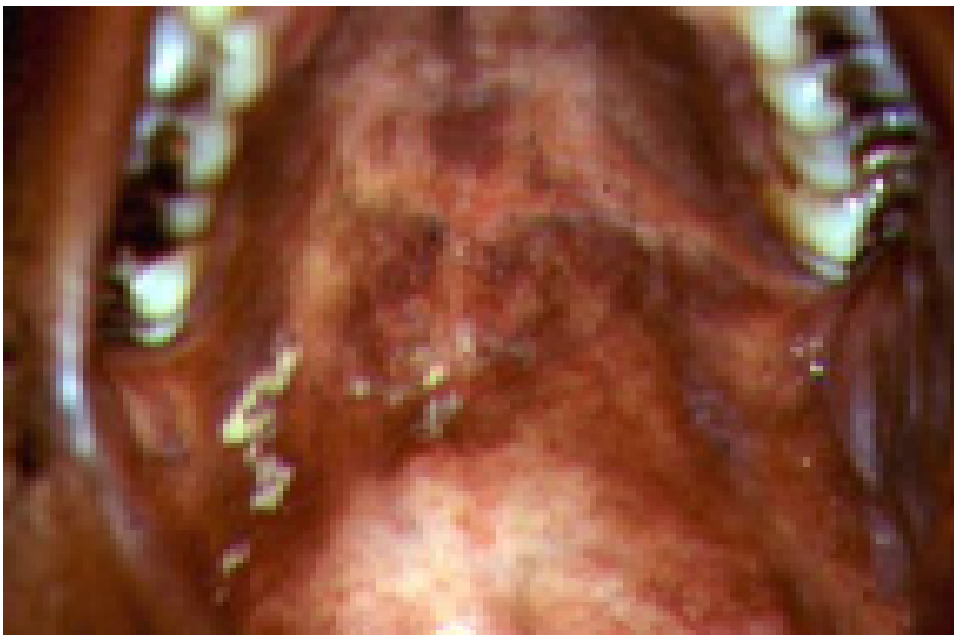Necrotizing aphthous stomatitis
photo courtesy Mark Schubert, DDS

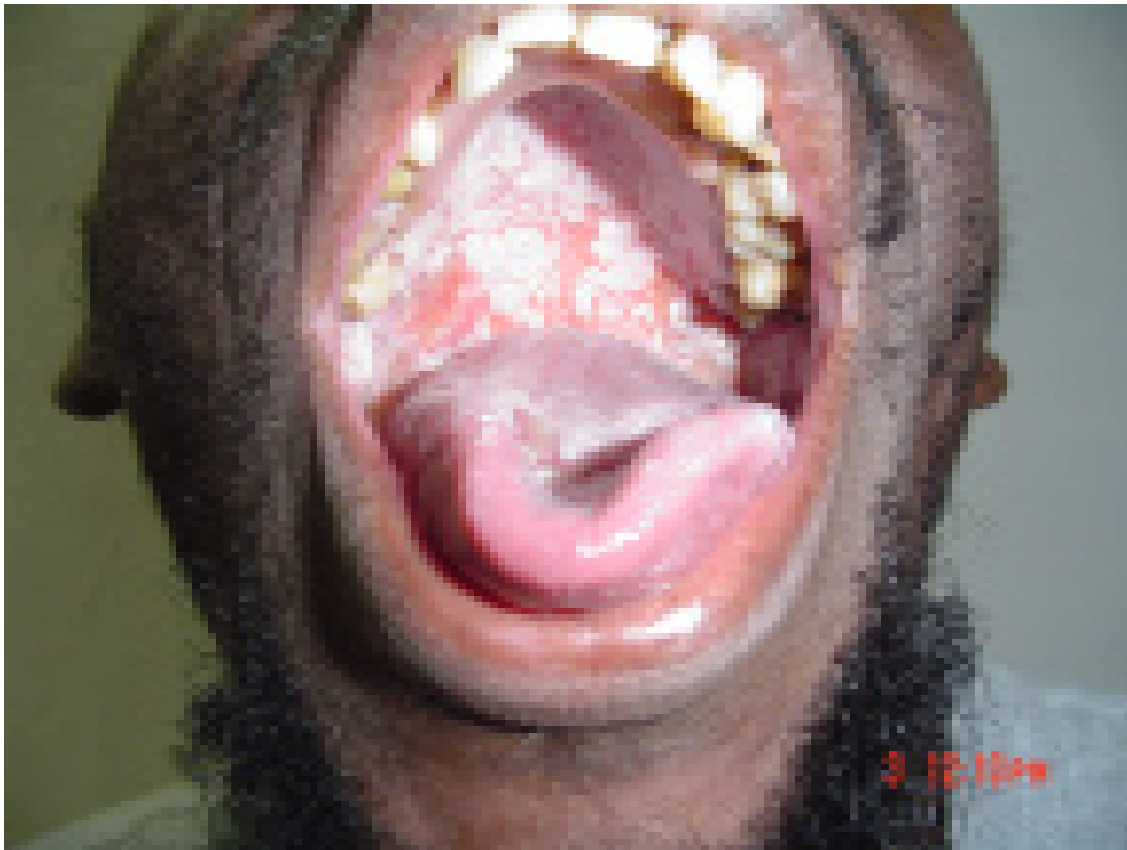




AZT-induced nail pigmentation changes
photo courtesy Jeffrey Edwards, MD

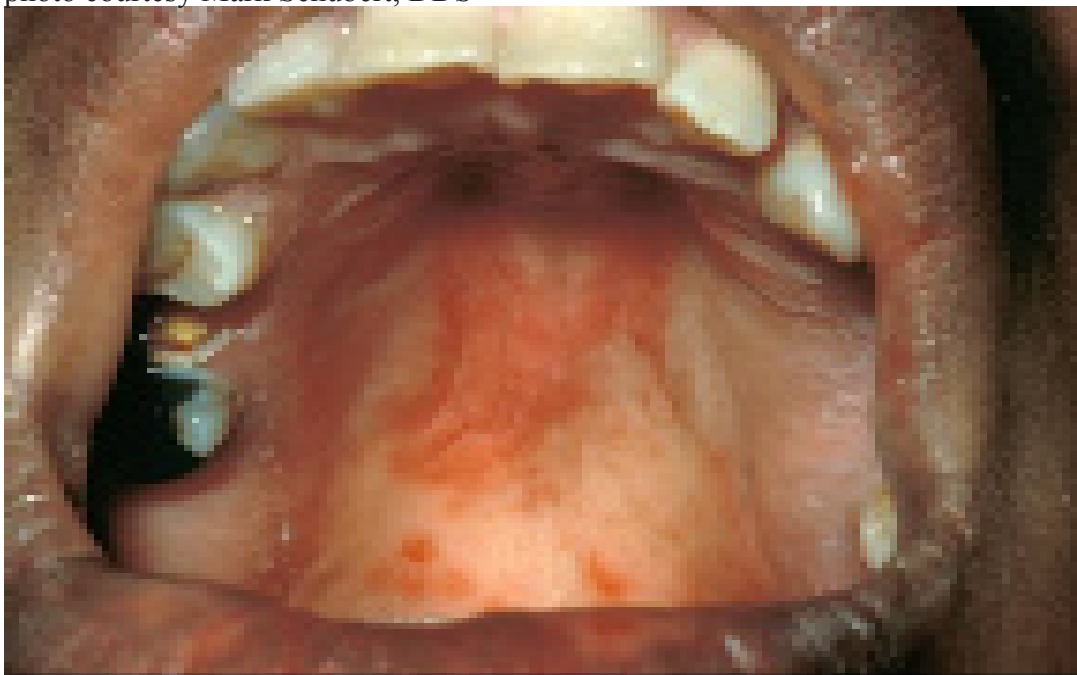AZT-induced hyperpigmentation of the palate
photo courtesy Mark Schubert, DDS

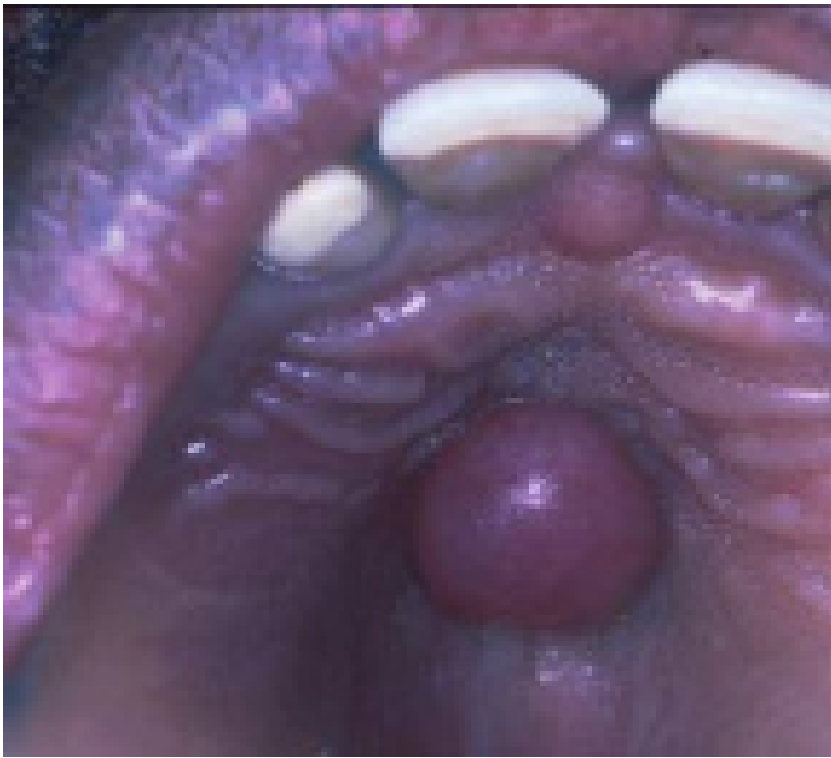



Candidiasis, pseudomembranous
photo courtesy Jeffrey Edwards, MD

Atrophic erythematous oral candidiasis
photo courtesy Mark Schubert, DDS

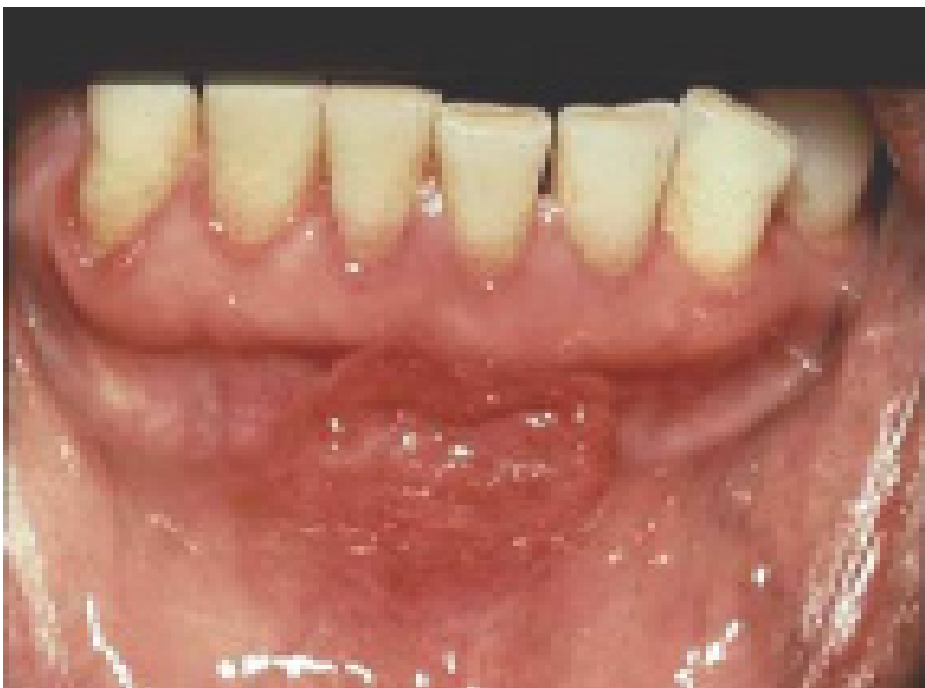


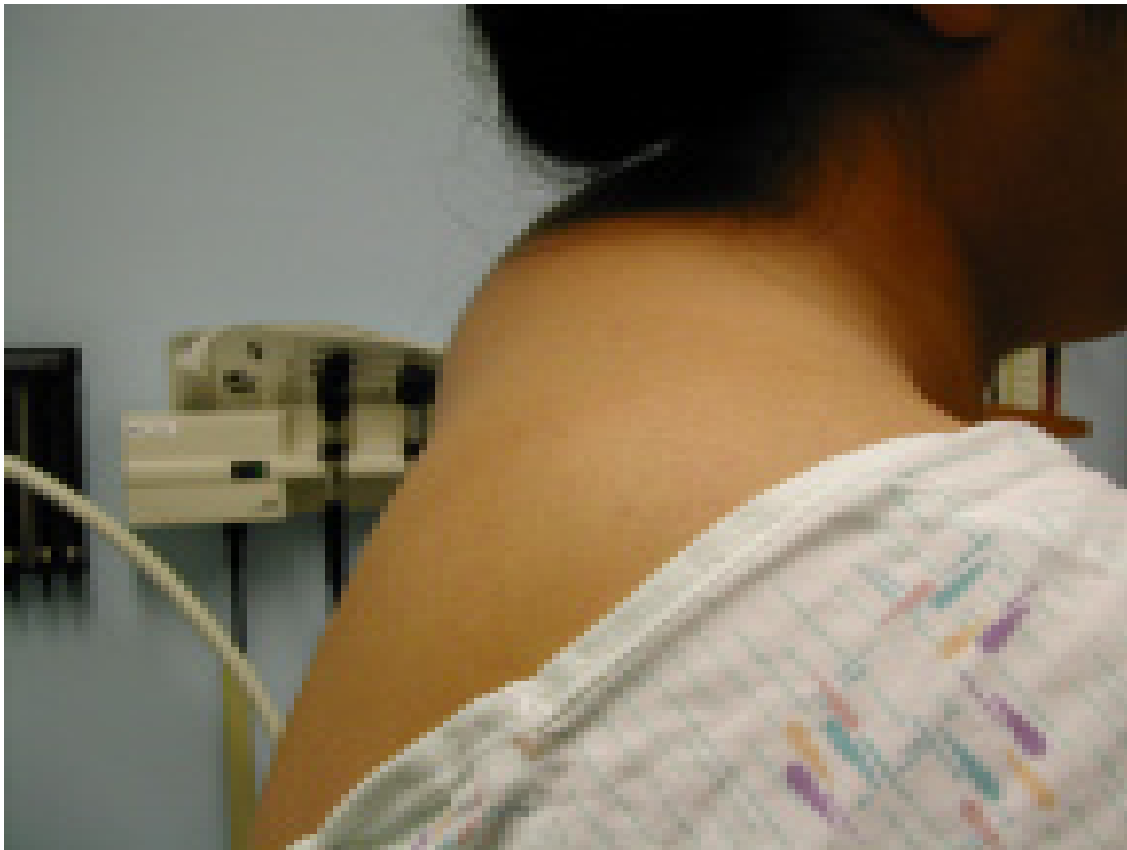
Bacillary Angiomatosis of the palate
photo courtesy Mark Schubert, DDS

CMV ulcer

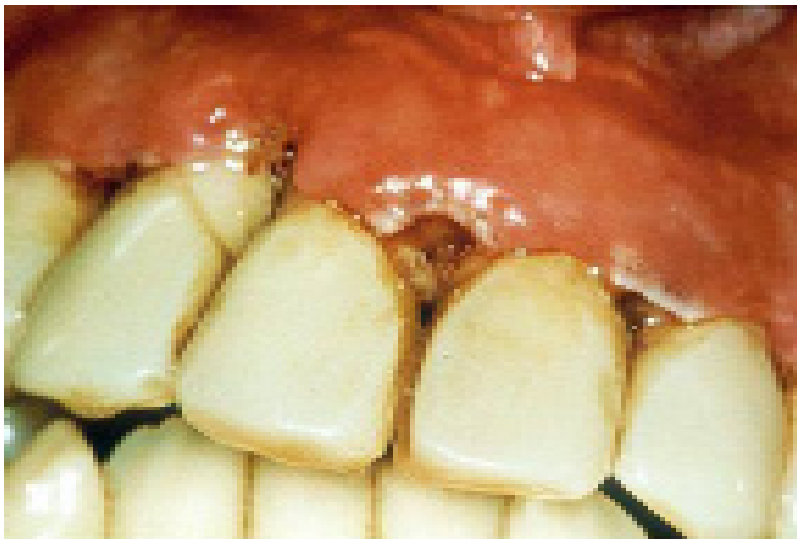
photo courtesy Mark Schubert, DDS

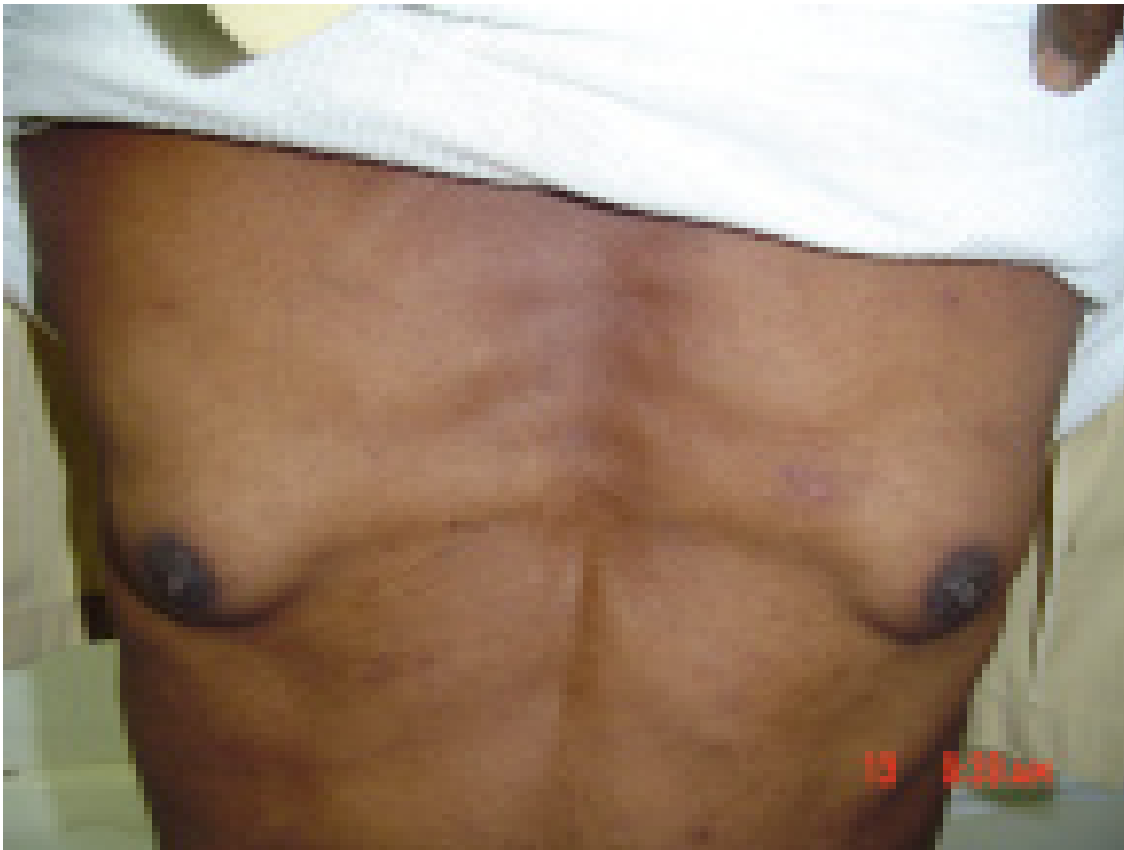



dorsocervical fat pad
photo courtesy Christopher Behrens, MD

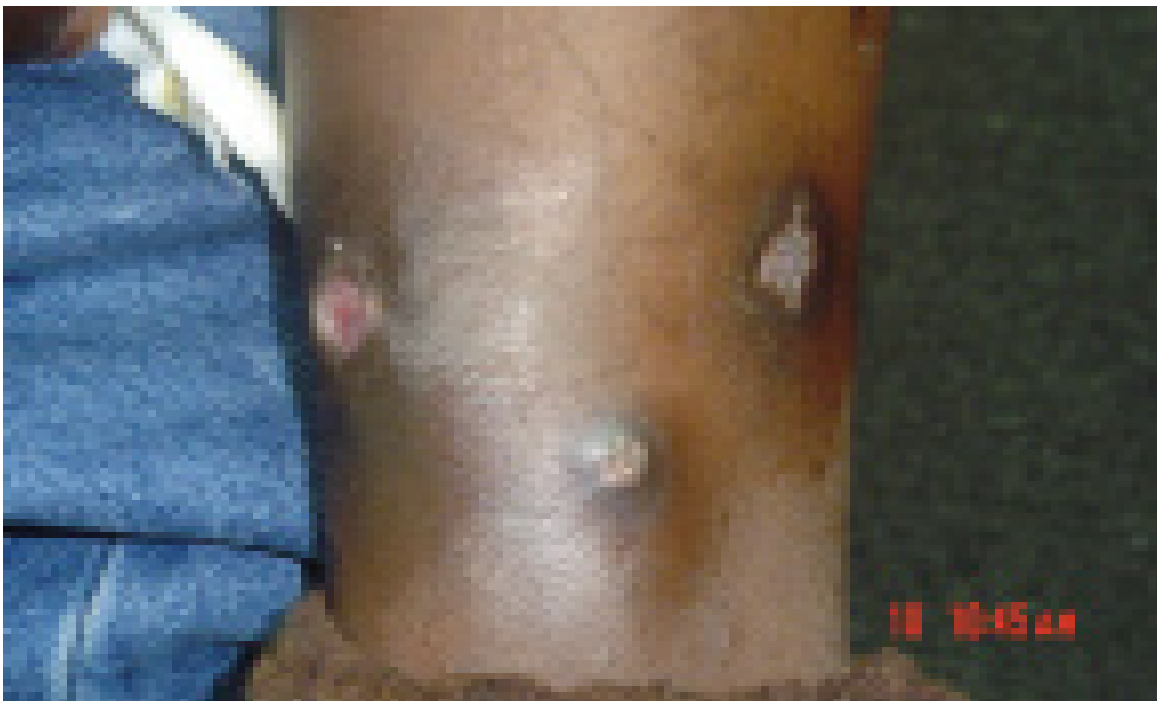Necrotizing gingivitis
photo courtesy Mark Schubert, DDS

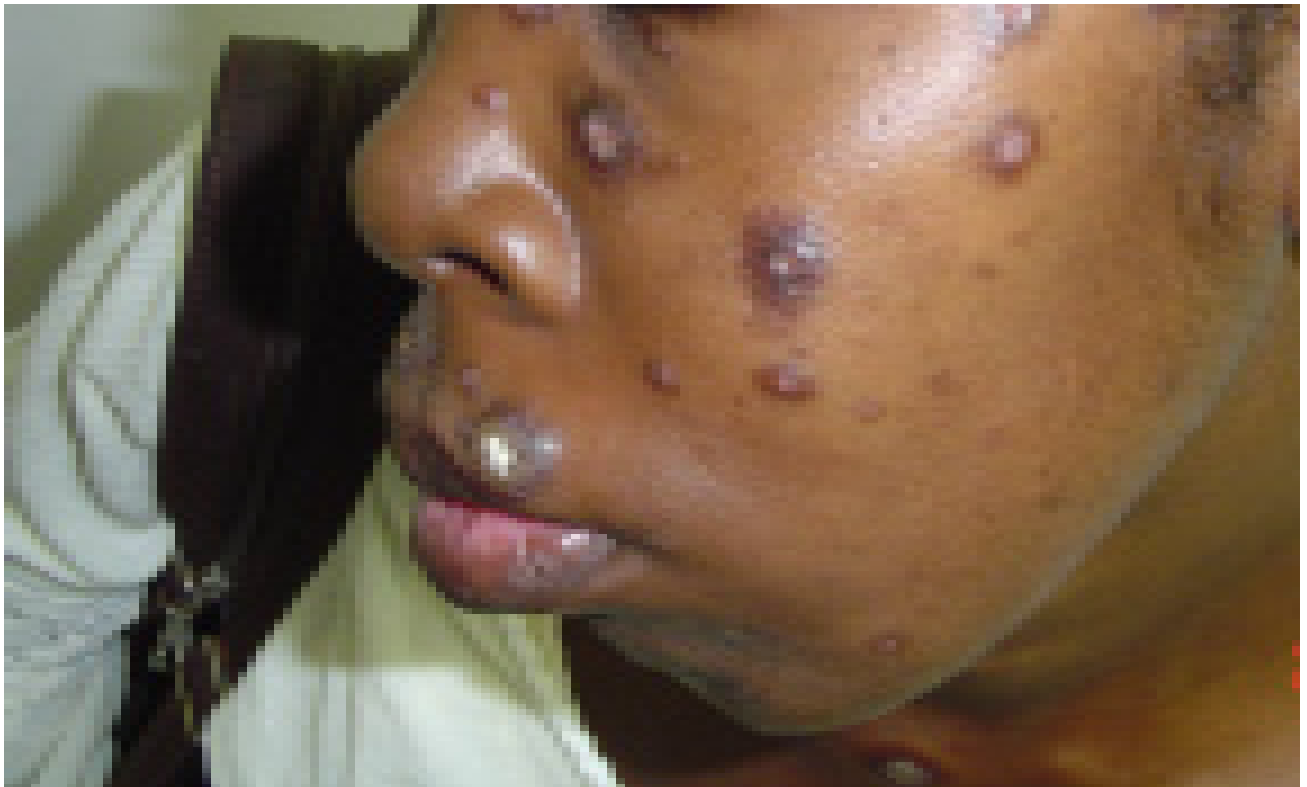



Gynecomastia
photo courtesy Jeffrey Edwards, MD

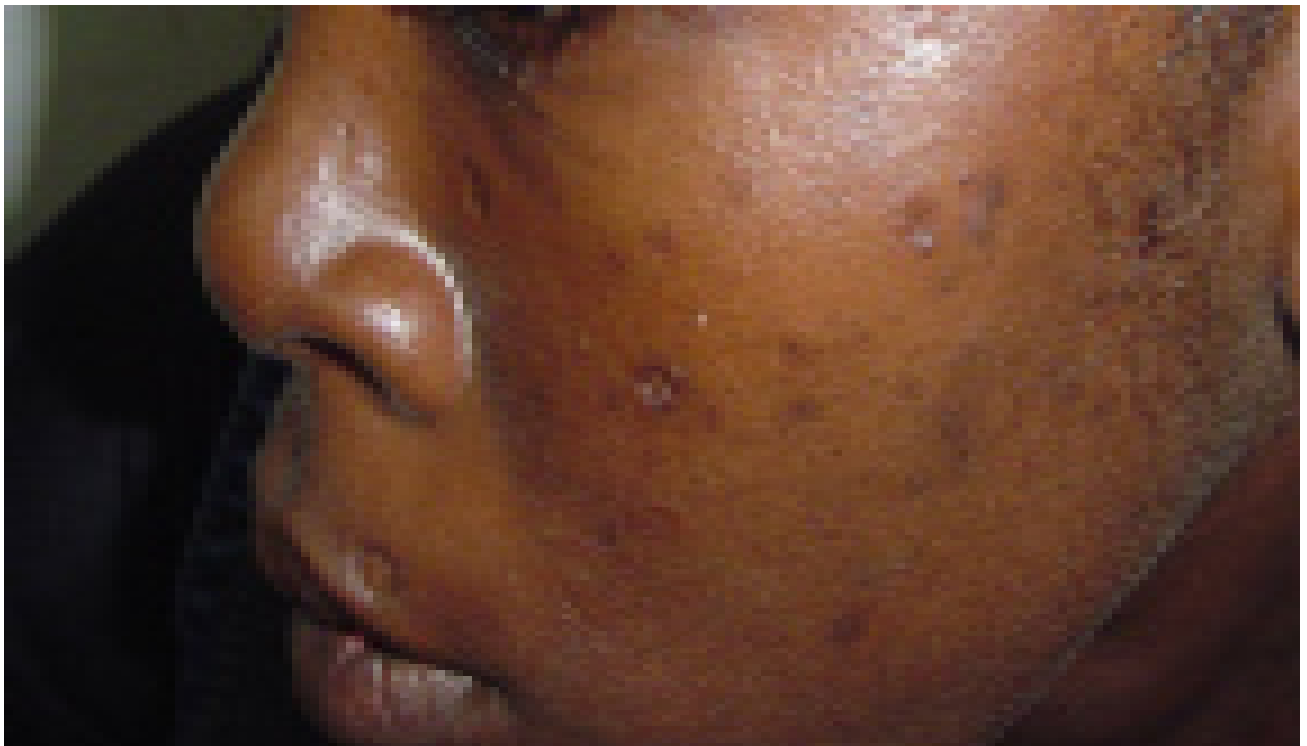Hansen's Disease (leprosy) Immune Reconstitution Syndrome
photo courtesy Jeffrey Edwards, MD

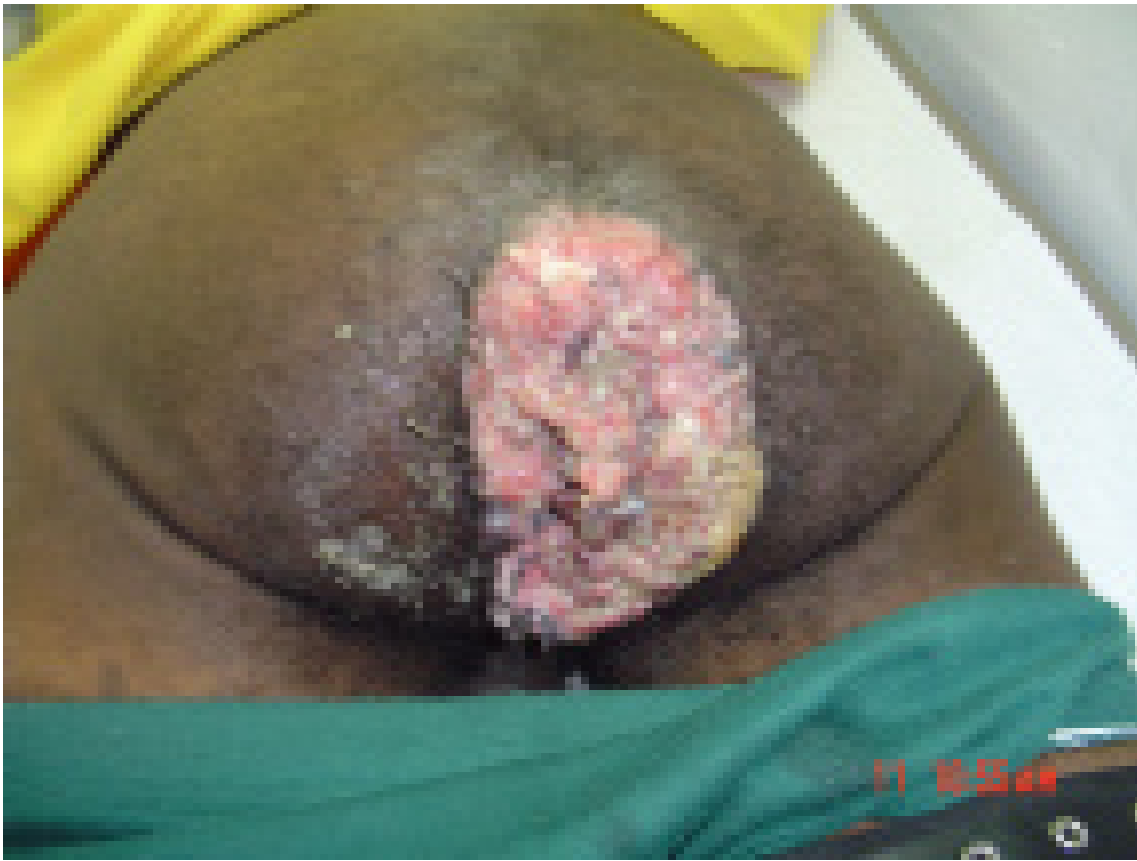



cutaneous histoplasmosis
photo courtesy Jeffrey Edwards, MD

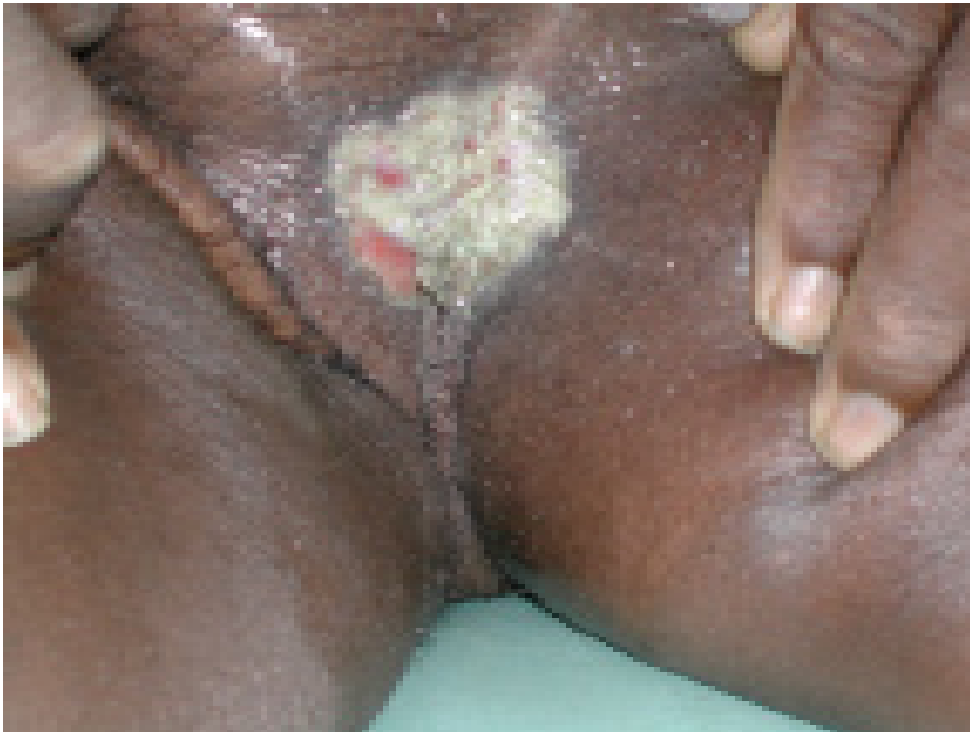cutaneous histoplasmosis, post 4 weeks of itraconazole therapy
photo courtesy Jeffrey Edwards, MD

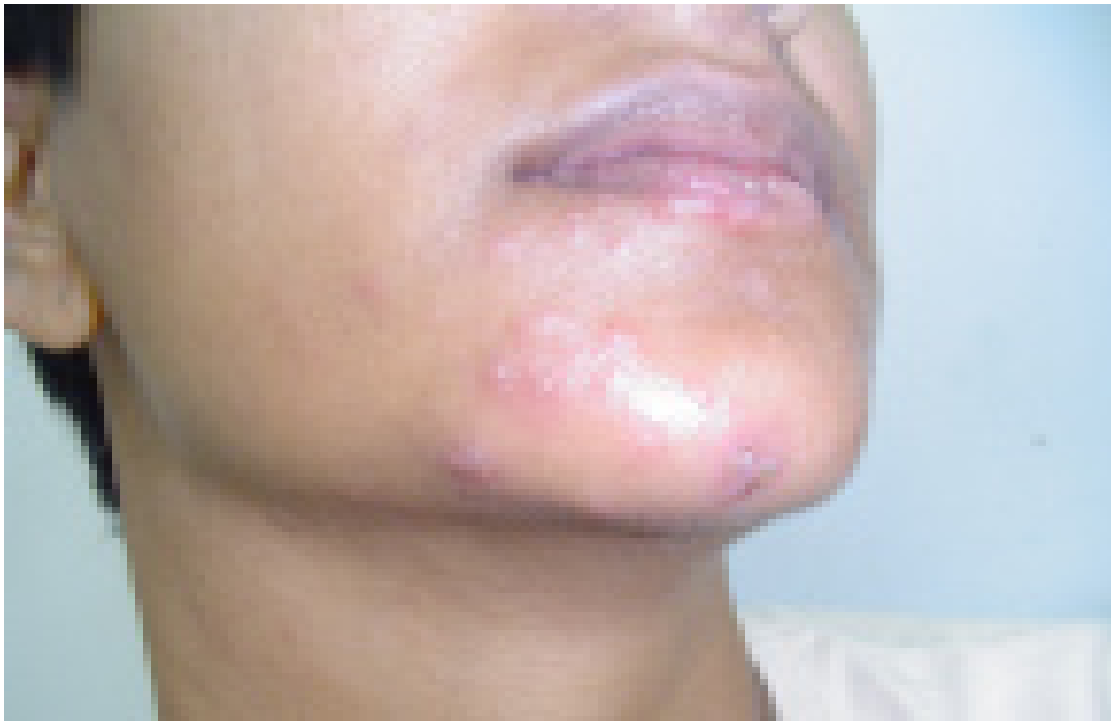



HPV-induced anal carcinoma
photo courtesy Jeffrey Edwards, MD

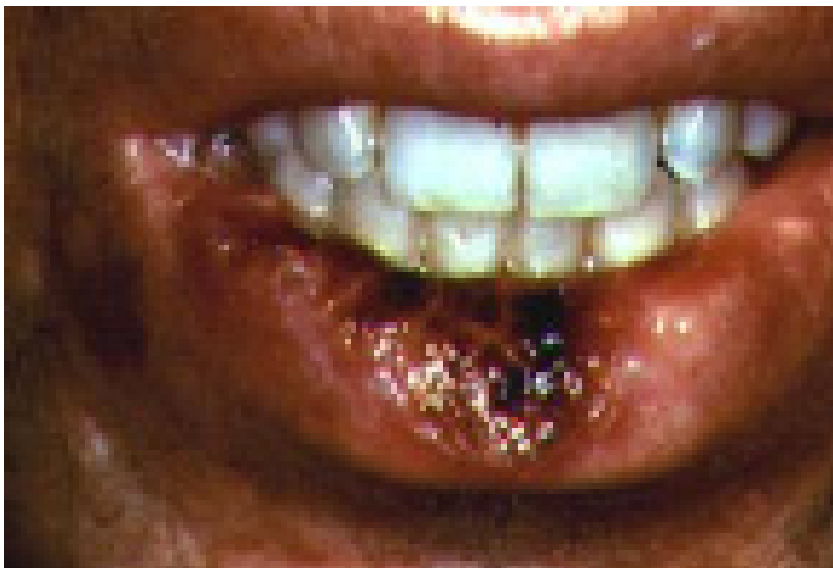Herpes simplex genitalis
photo courtesy Jeffrey Edwards, MD

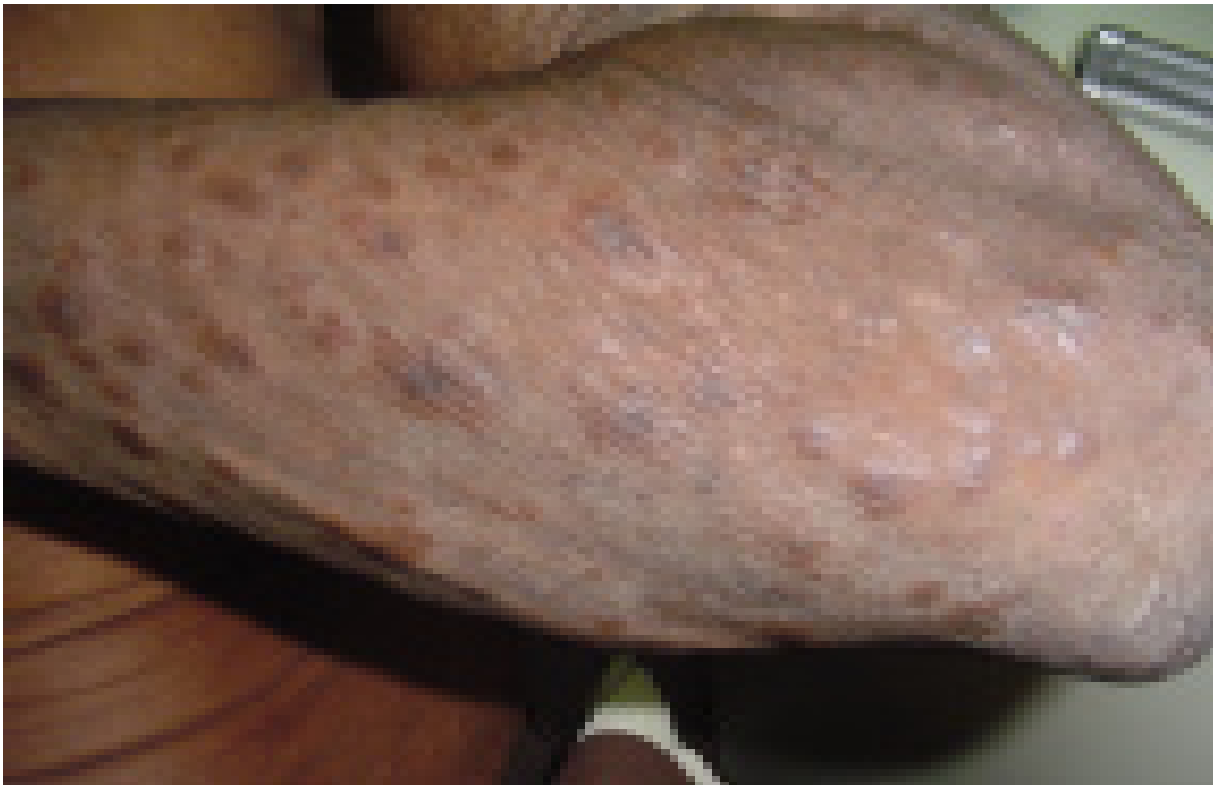



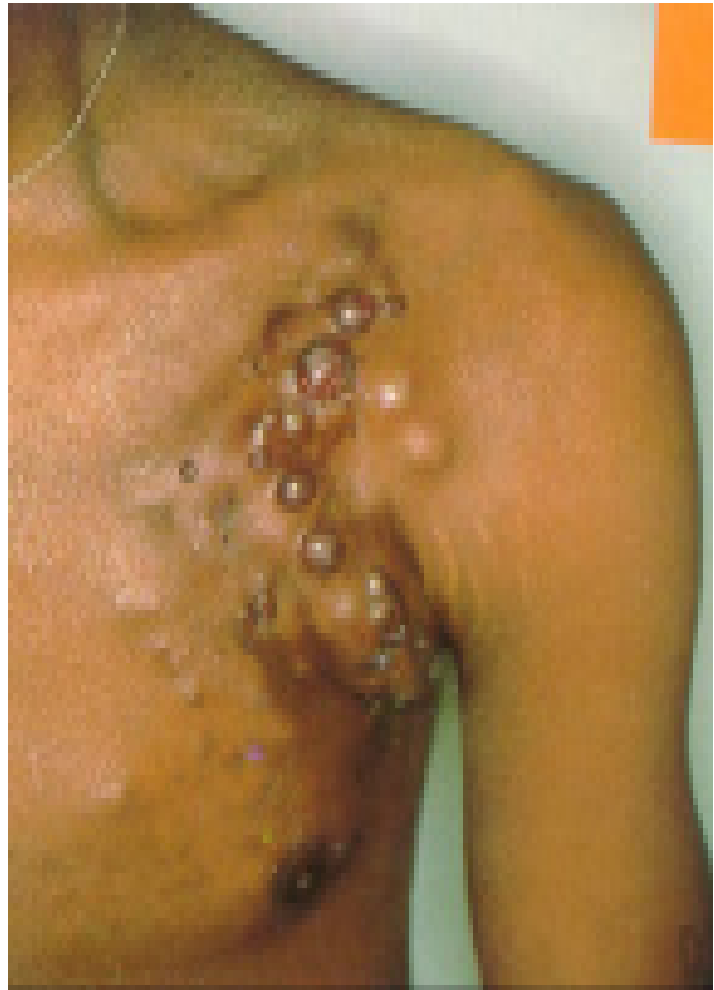Orolabial herpes simplex infection
photo courtesy Jeffrey Edwards, MD

HSV stomatitis
photo courtesy Mark Schubert, DDS

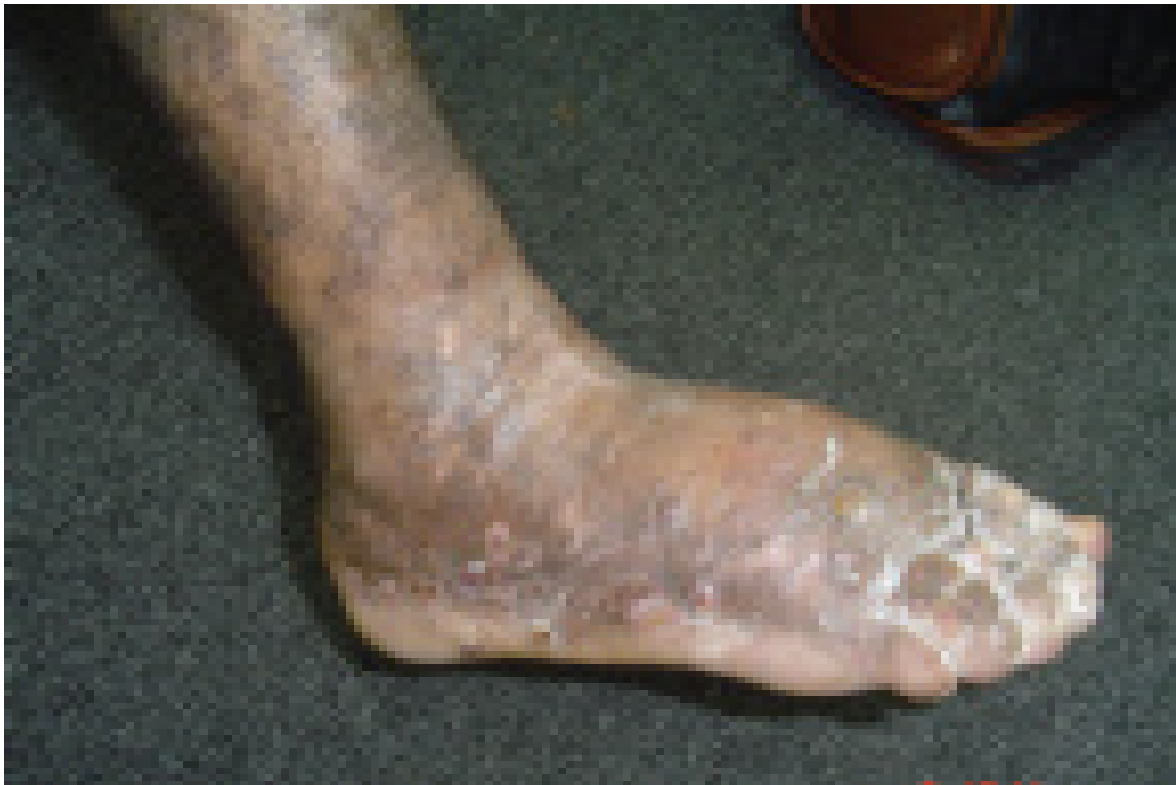



cutaneous HTLV-1 lymphoma
photo courtesy Jeffrey Edwards, MD

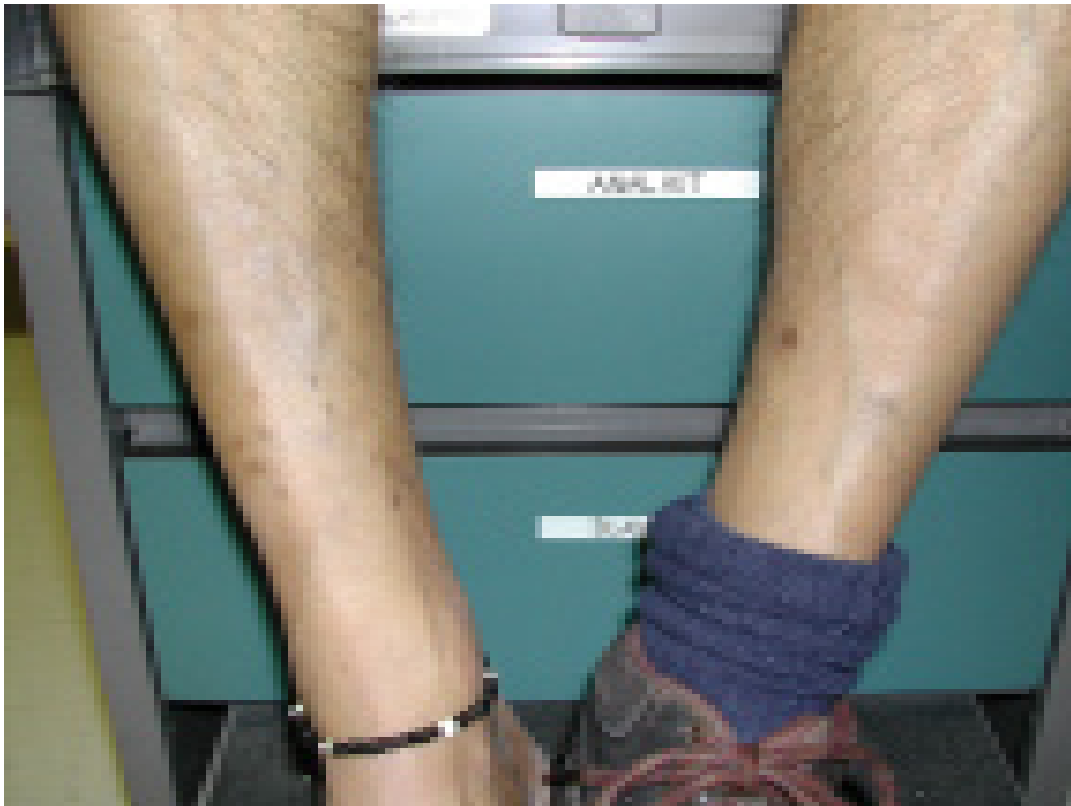

Kaposi Sarcoma of axilla and chest wall
photo courtesy Beth Schenck, MD

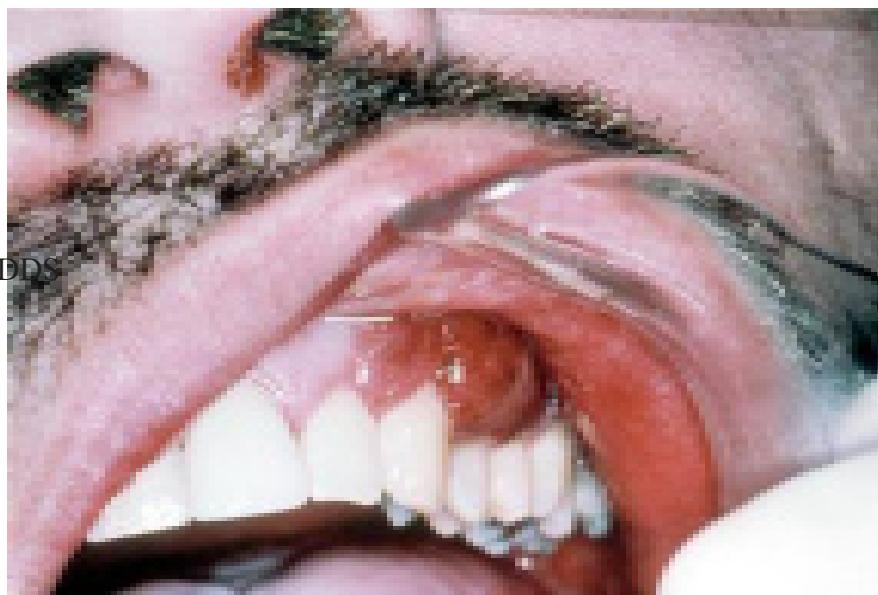

Kaposi Sarcoma of the lower extremity
photo courtesy Jeffrey Edwards, MD

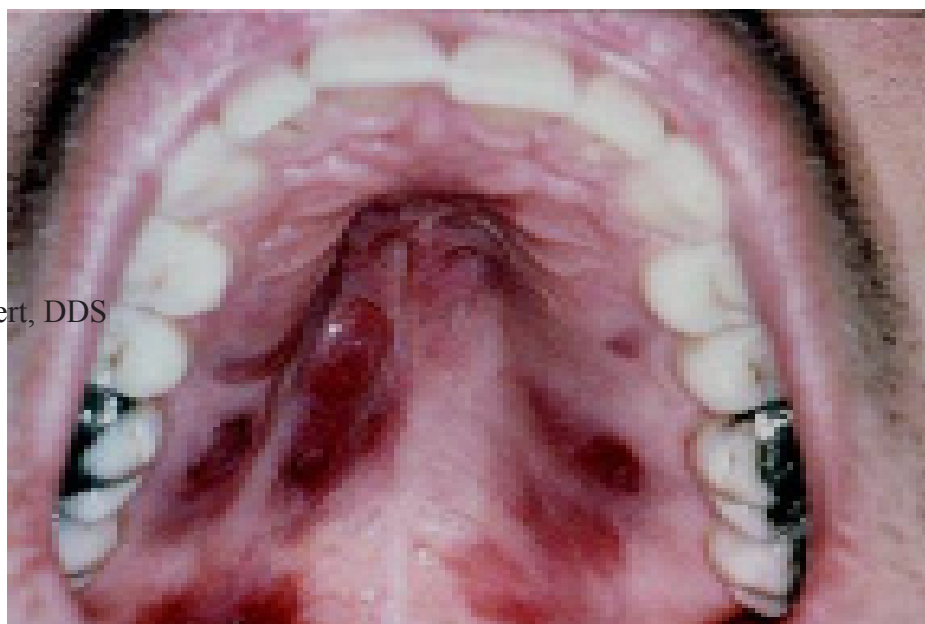Kaposi Sarcoma of lower extremities, post therapy with doxorubicin and HAART
photo courtesy Christopher Behrens, MD



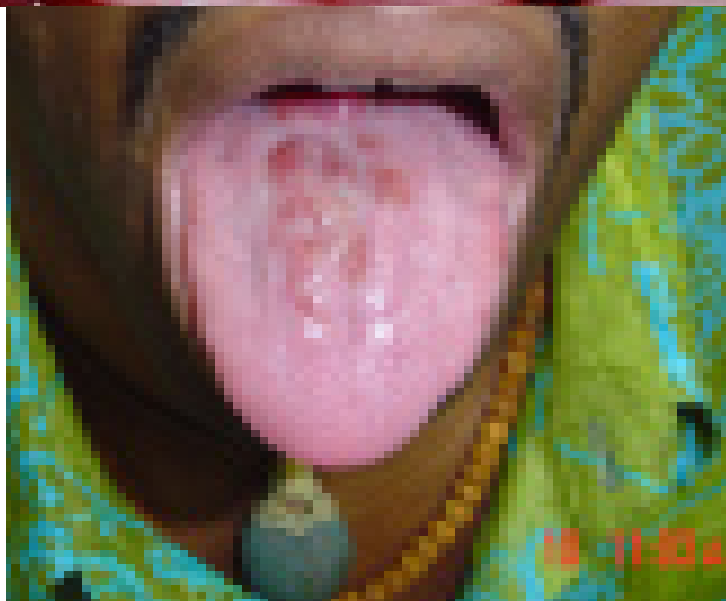
Kaposi Sarcoma, gingiva
photo courtesy Mark Schubert, DDS

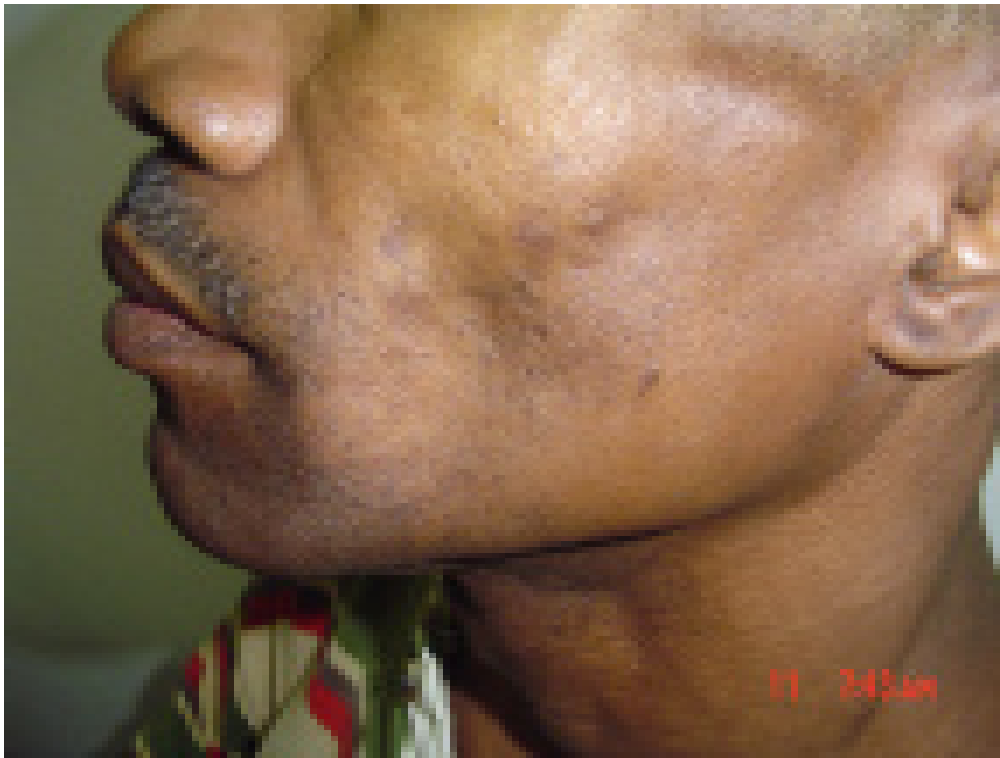

Kaposi Sarcoma, palate
photo courtesy Mark Schubert, DDS



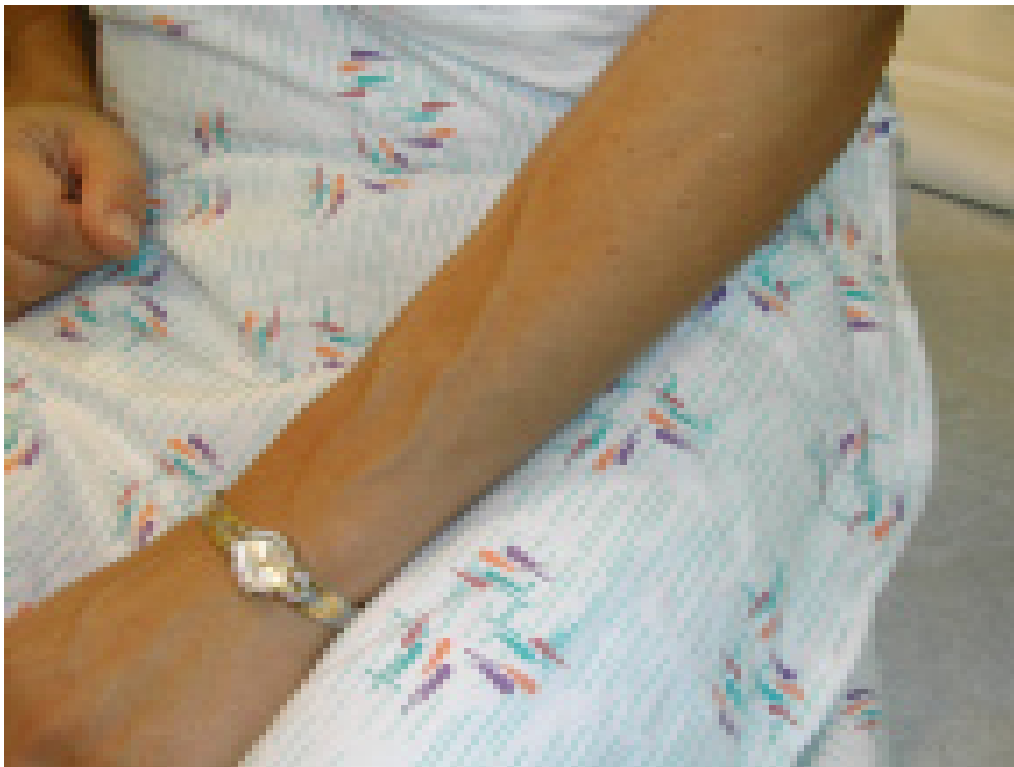Kaposi Sarcoma, tongue
photo courtesy Jeffrey Edwards, MD

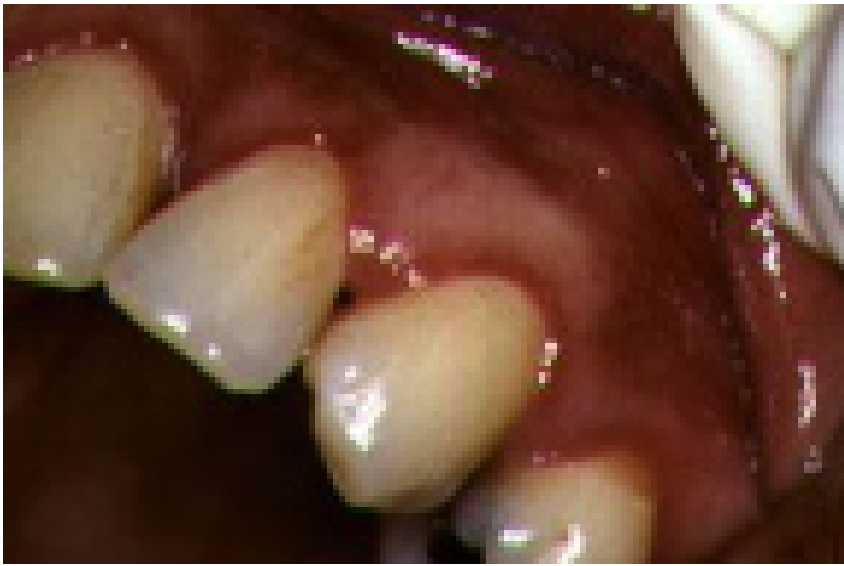



Facial lipoatrophy secondary to stavudine (d4T)
photo courtesy Jeffrey Edwards, MD

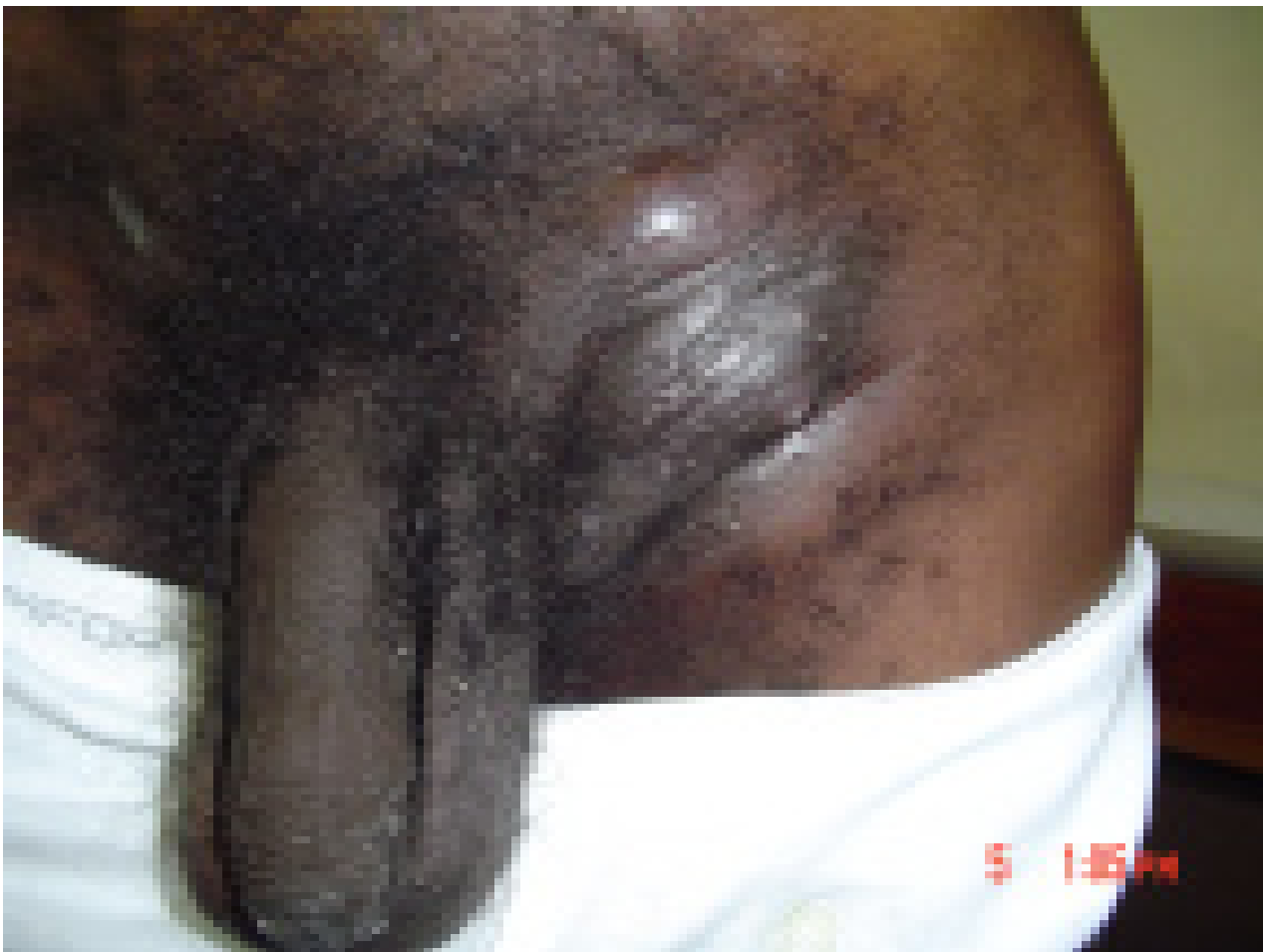Peripheral lipoatrophy secondary to stavudine (d4T)
photo courtesy Christopher Behrens, MD

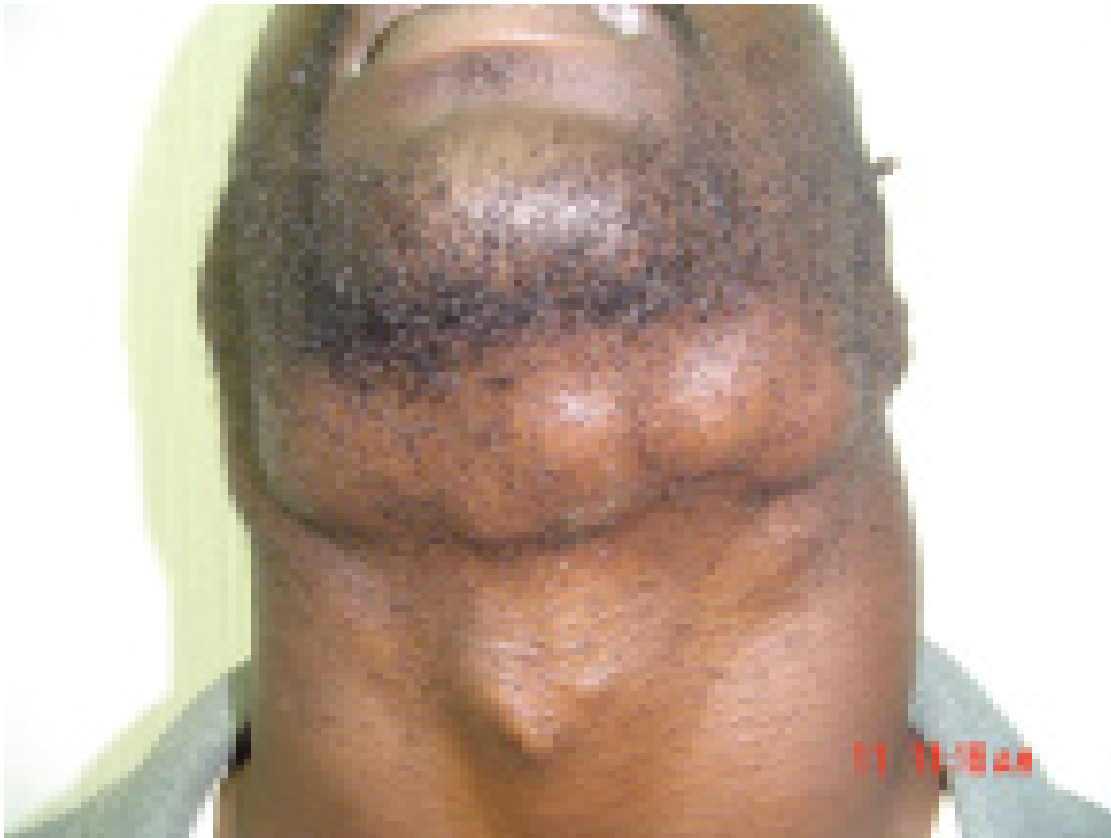



Linear Gingival Erythema (LRE)
photo courtesy Mark Schubert, DDS

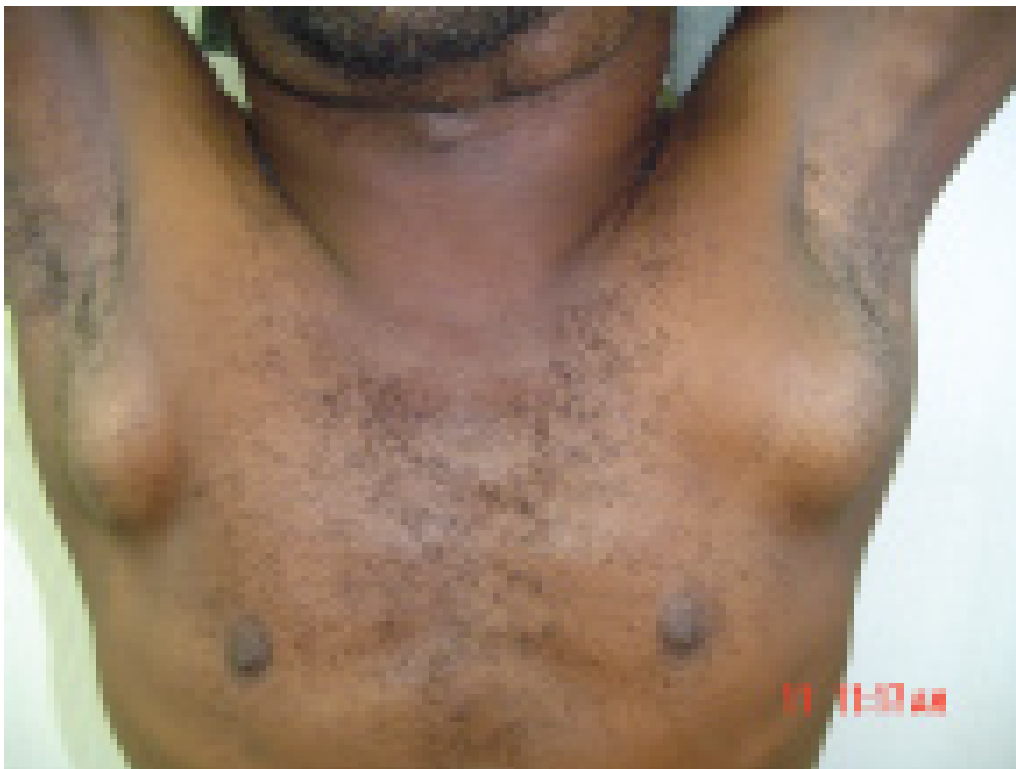Lymphogranuloma venereum
photo courtesy Jeffrey Edwards, MD

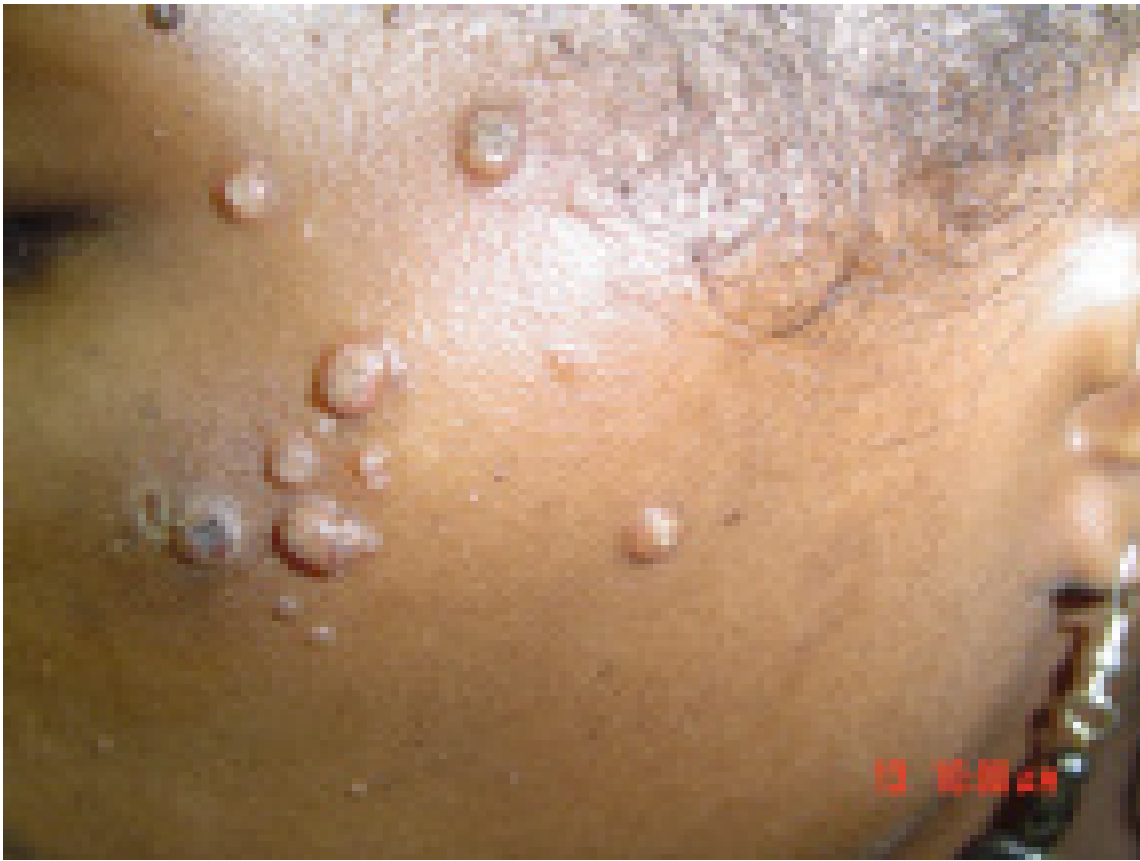



Non-Hodgkin's Lymphoma
photo courtesy Jeffrey Edwards, MD

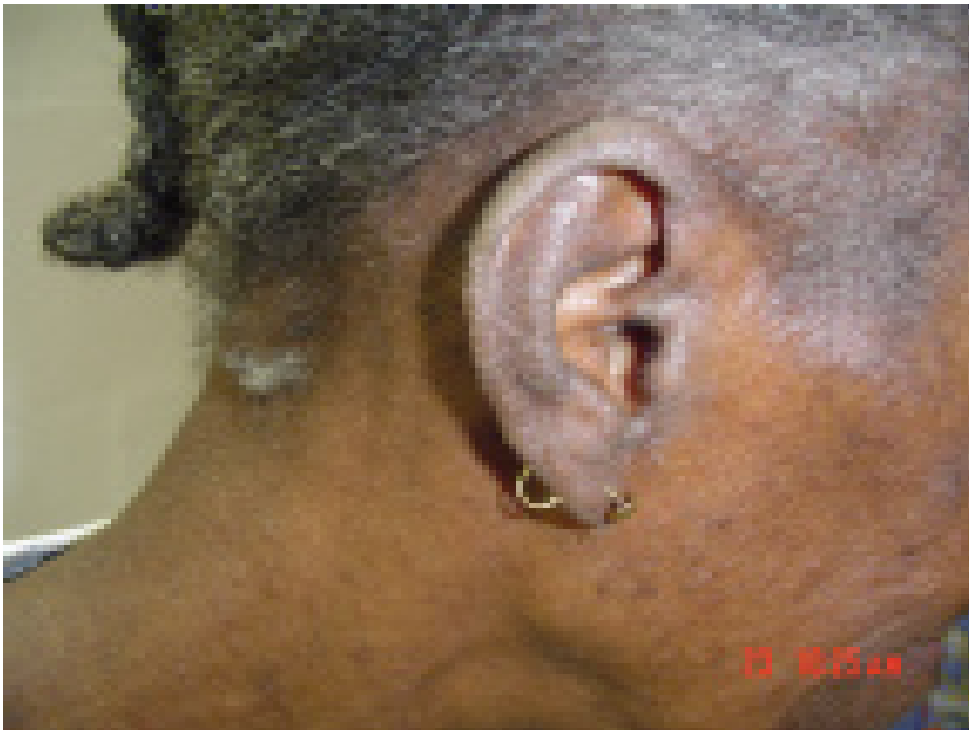Non-Hodgkin's Lymphoma
photo courtesy Jeffrey Edwards, MD

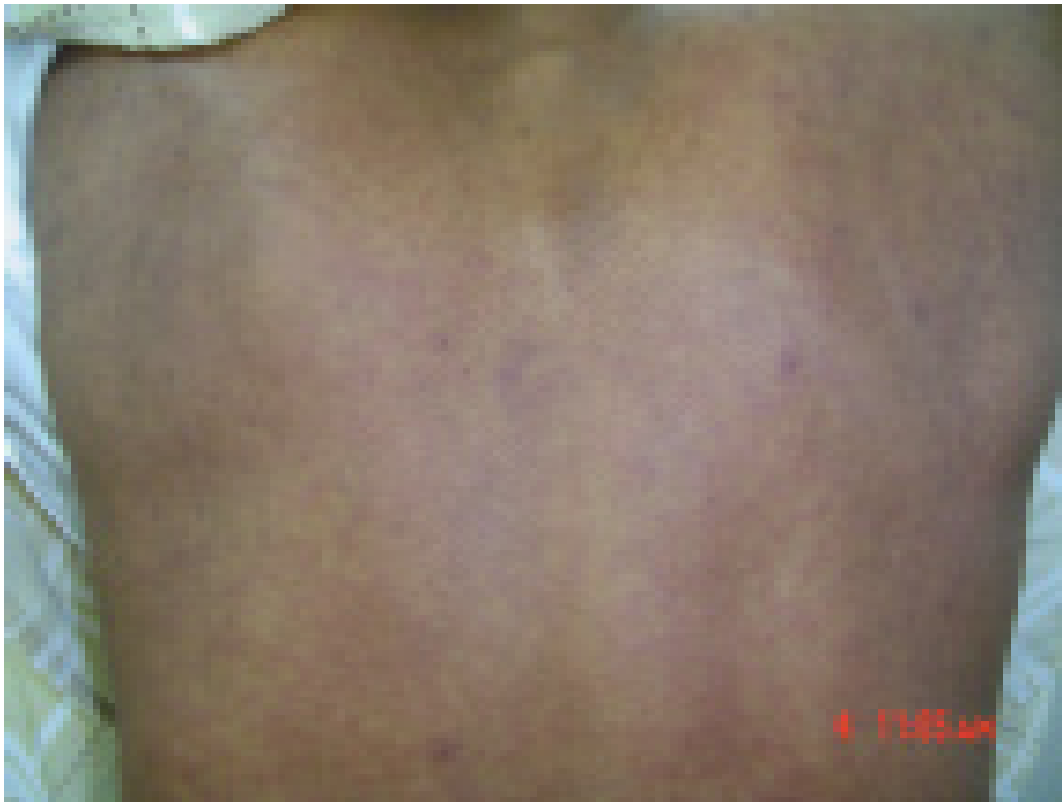



Molluscum contagiosum
photo courtesy Jeffrey Edwards, MD

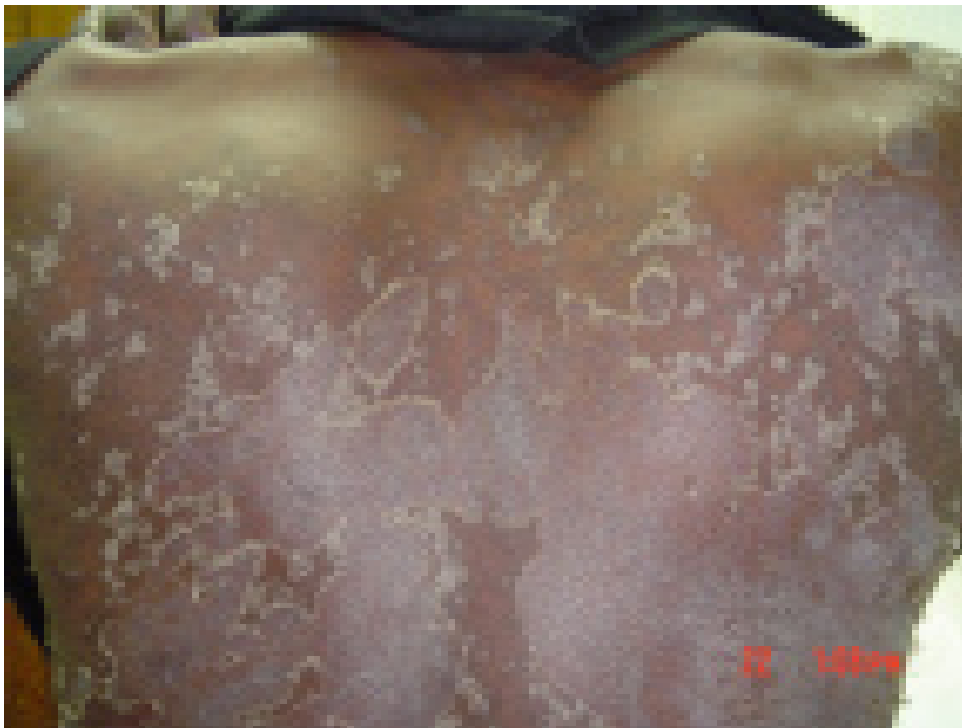Norwegian Scabies
photo courtesy Jeffrey Edwards, MD

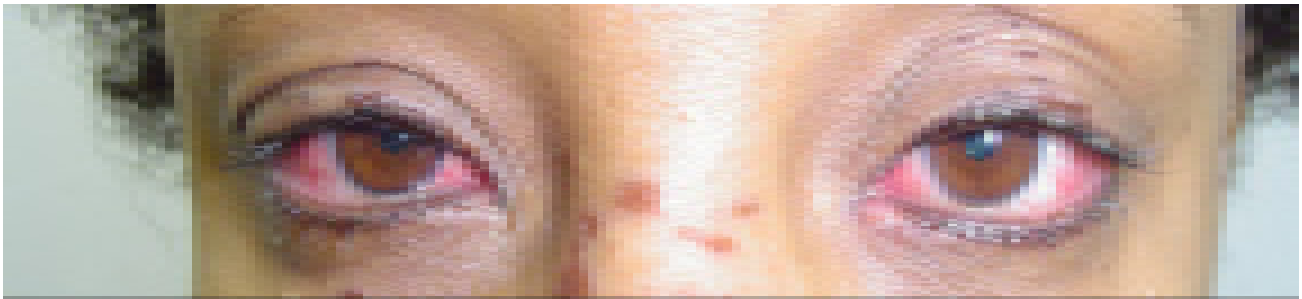
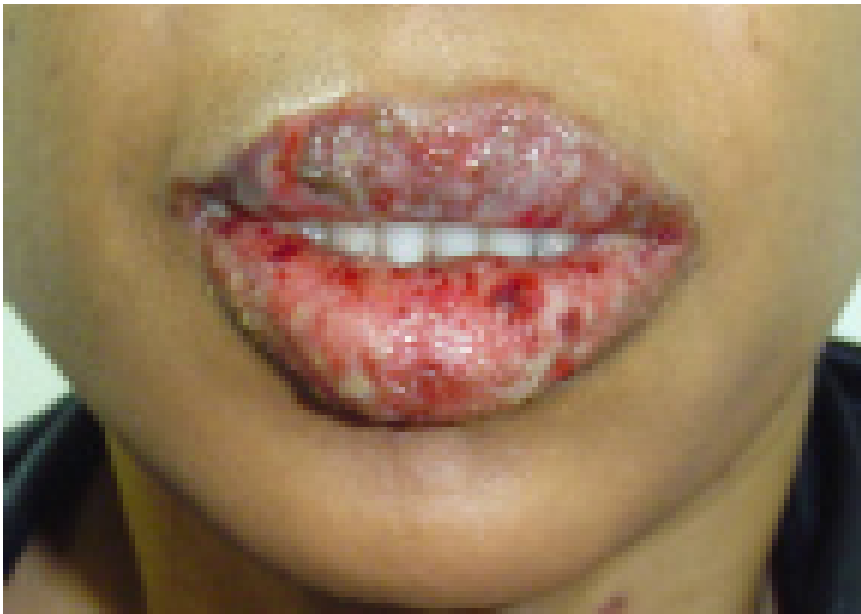



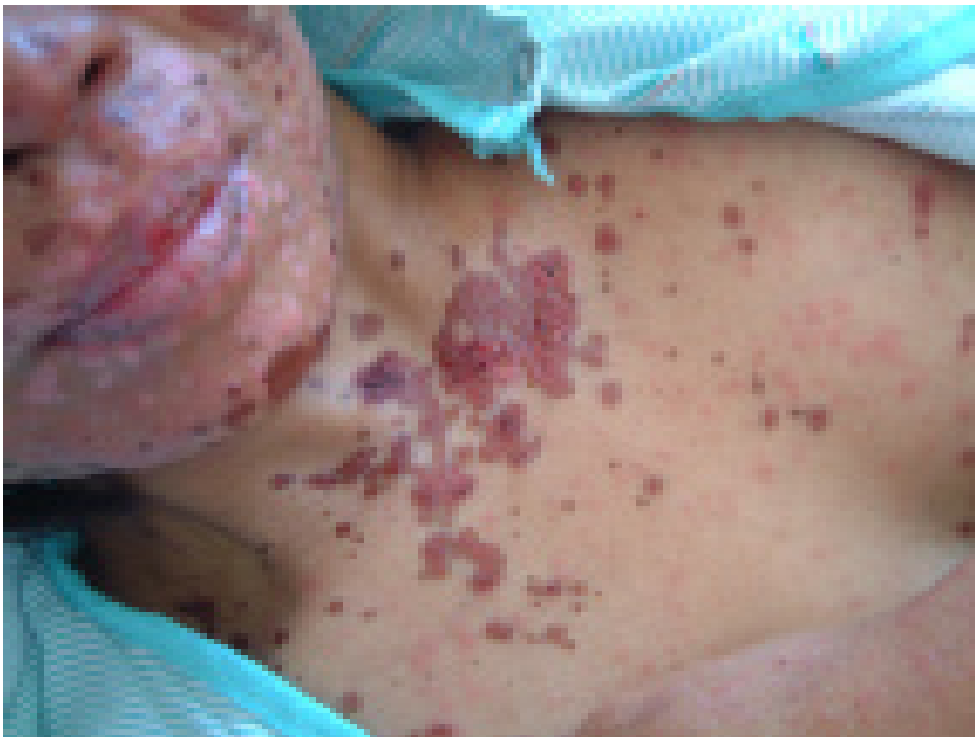Nevirapine hypersensitivity rash (mild)
photo courtesy Jeffrey Edwards, MD

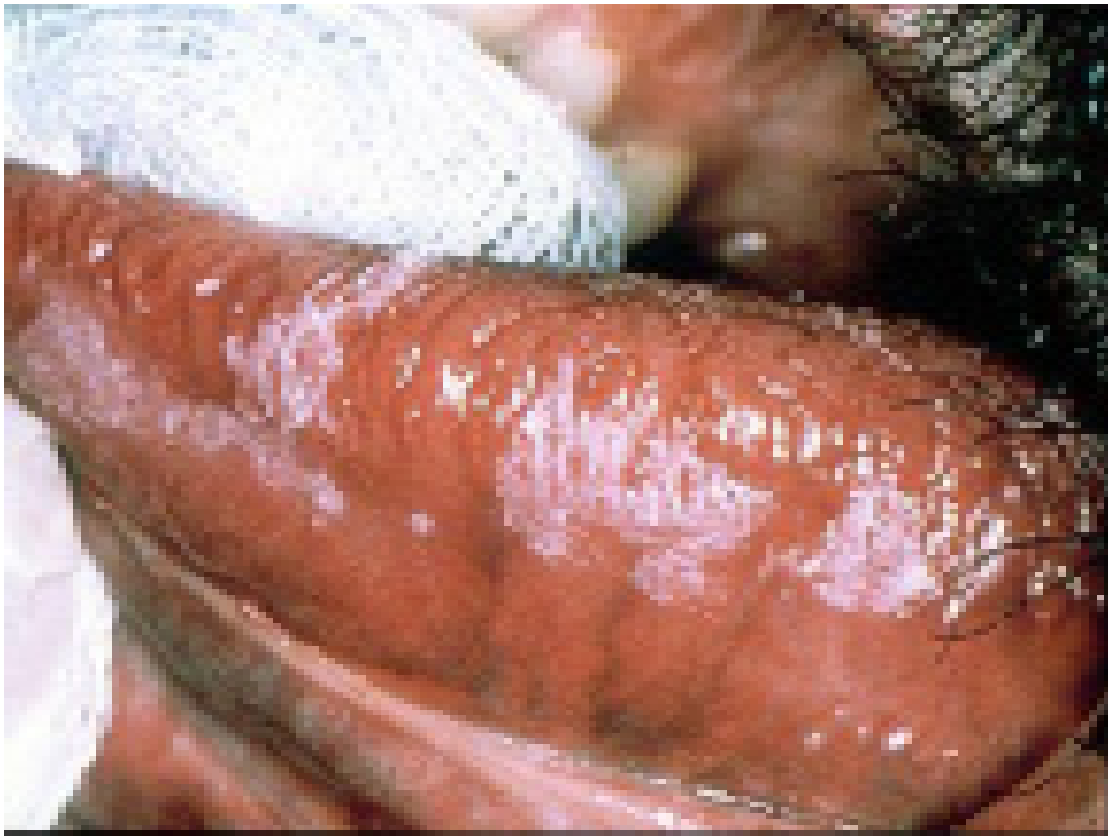Nevirapine hypersensitivity rash (more severe)
photo courtesy Jeffrey Edwards, MD



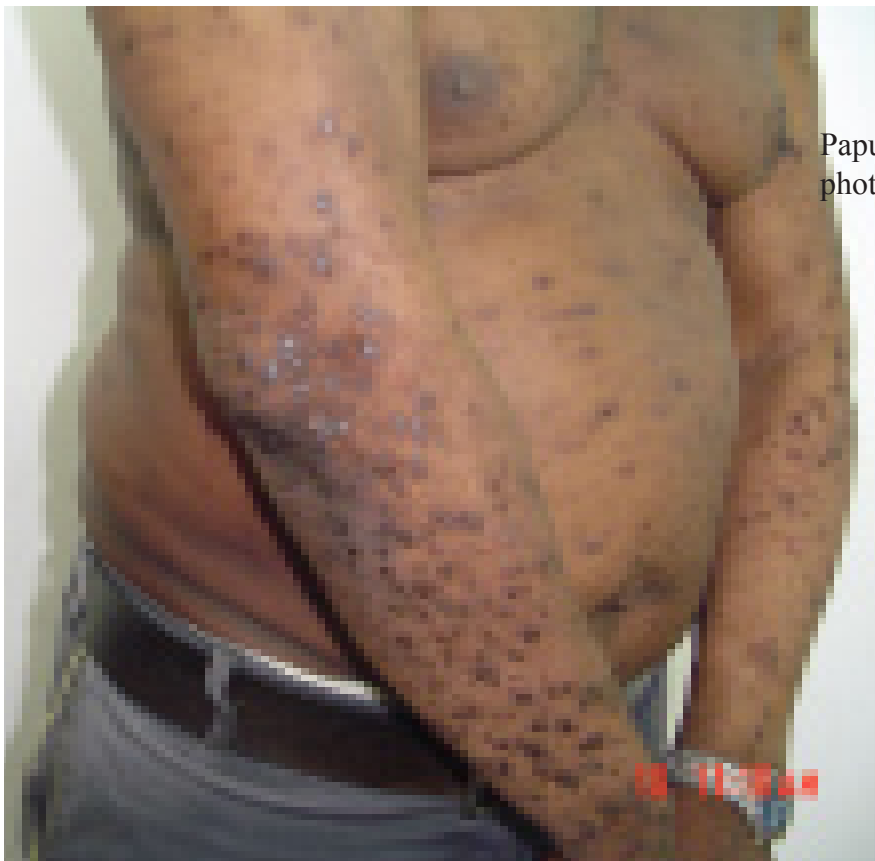

Nevirapine-induced Stevens Johnson Syndrome
photos courtesy Jeffrey Edwards, MD and Robert Harrington, MD

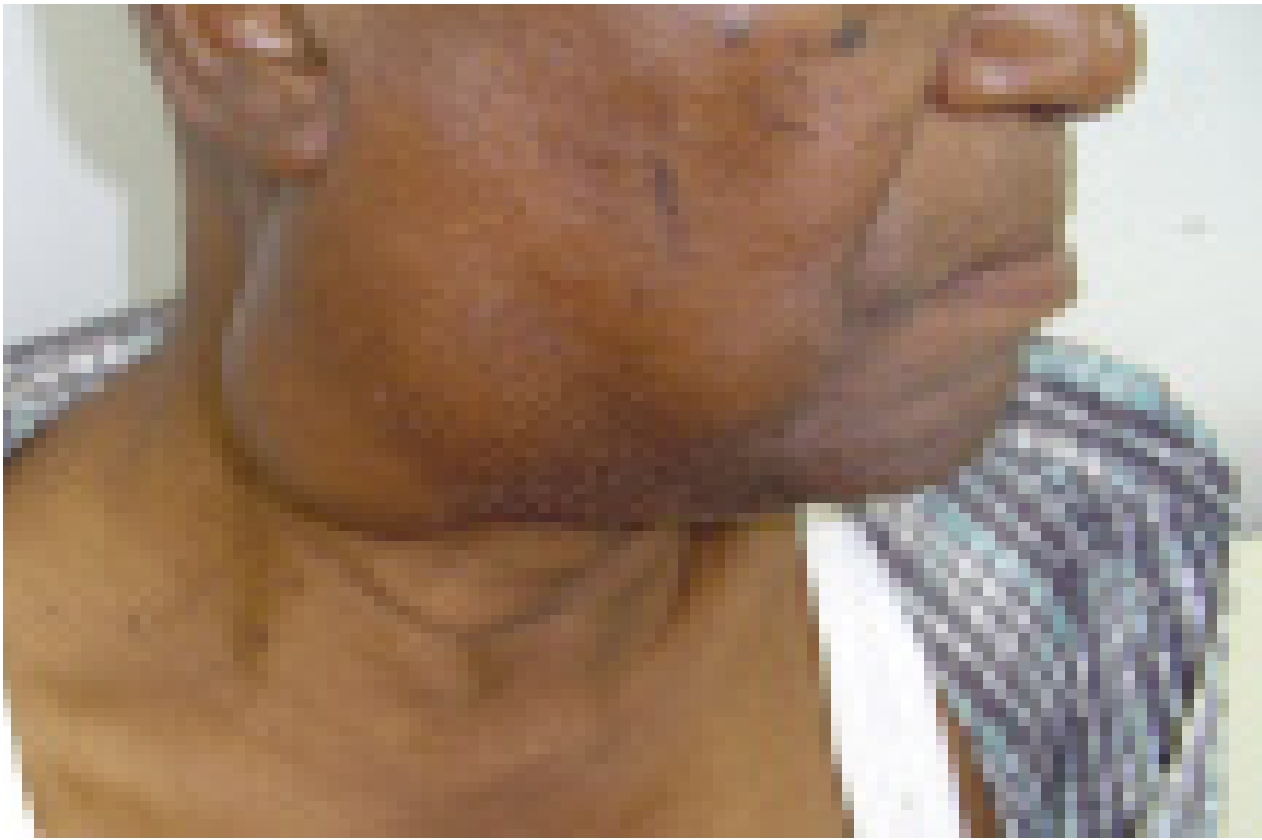



Oral Hairy Leukoplakia
photo courtesy Mark Schubert, DDS

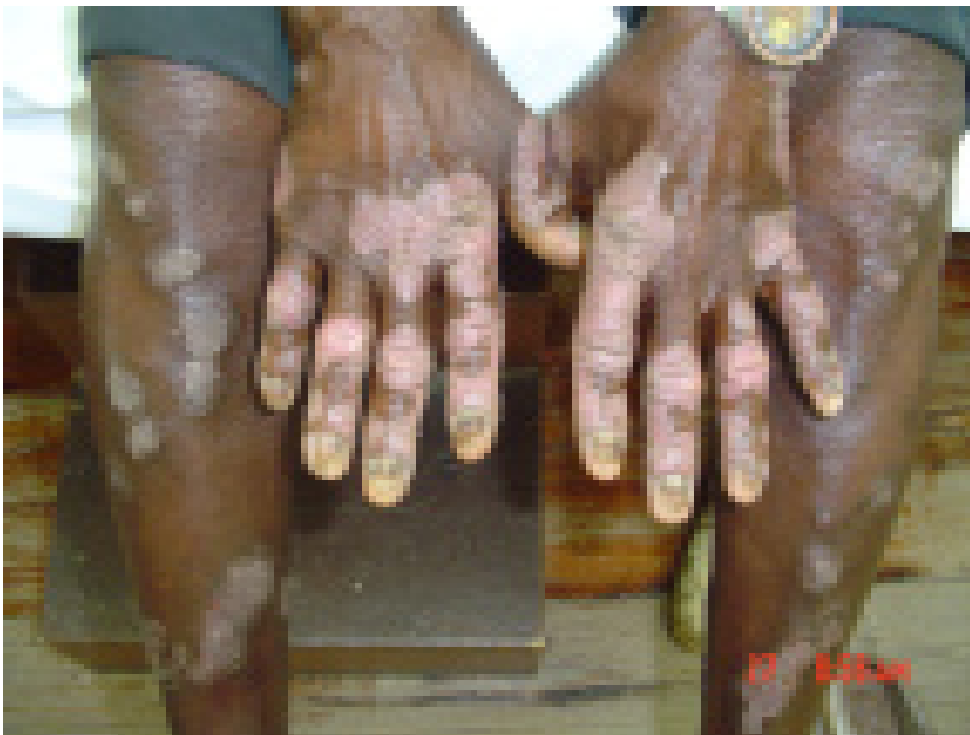

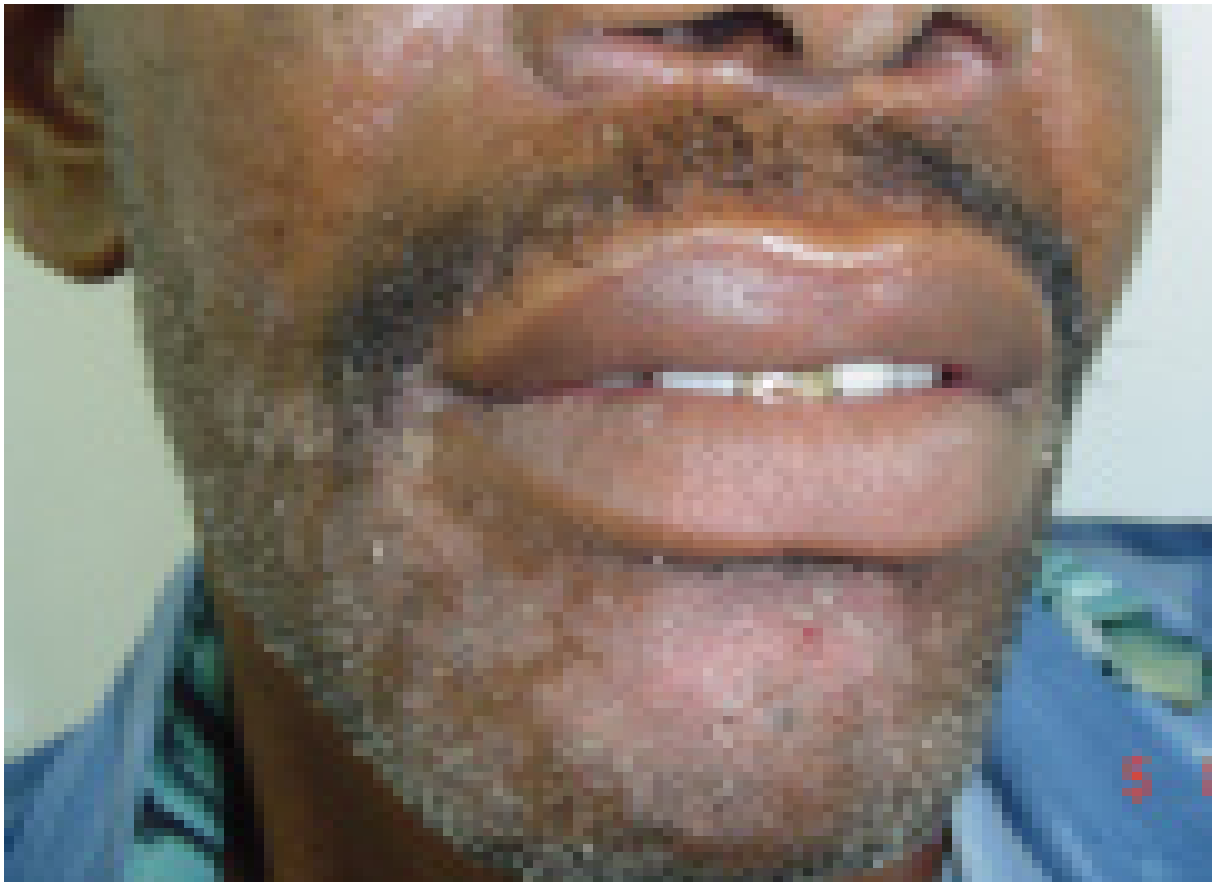Papular prurigo
photo courtesy Jeffrey Edwards, MD



Parotid gland enlargement
photo courtesy Jeffrey Edwards, MD

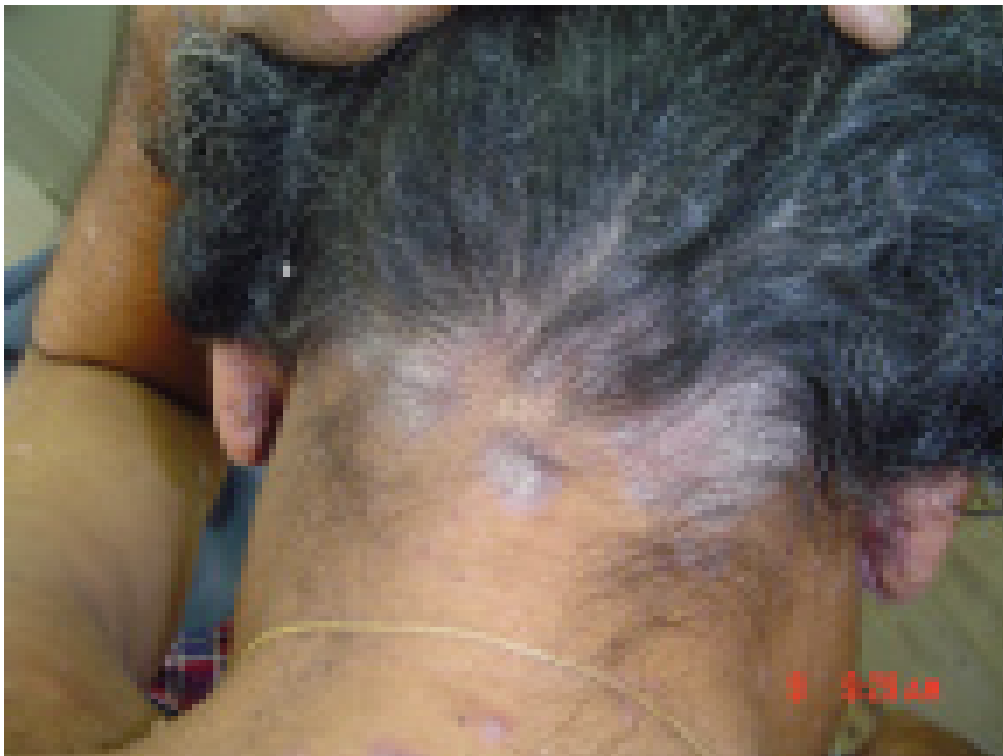Psoriasis
photo courtesy Jeffrey Edwards, MD

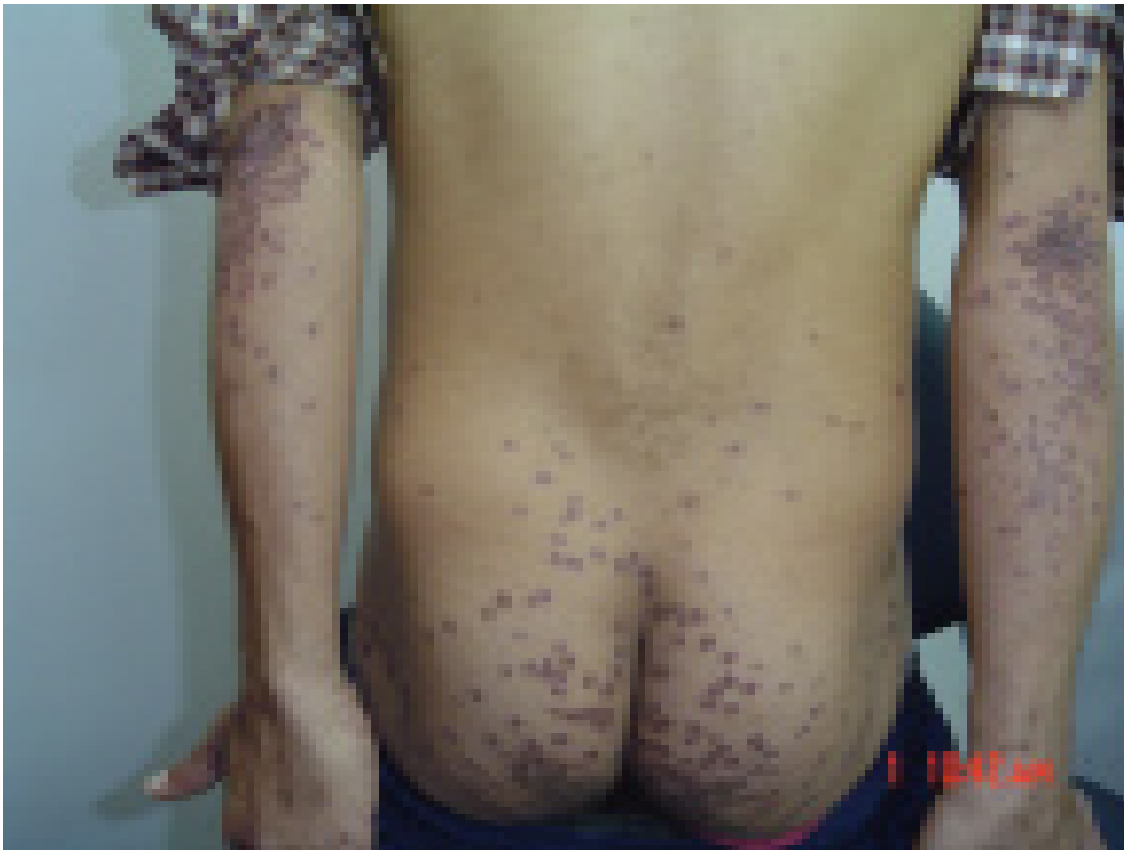



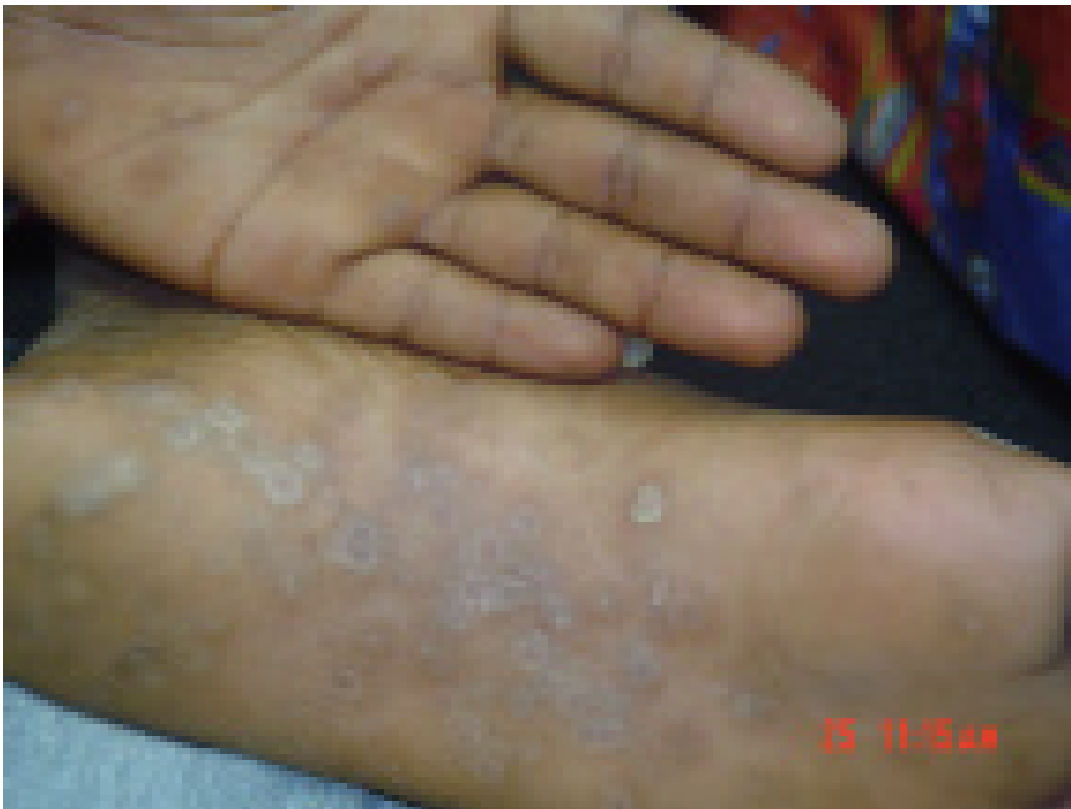Seborrheic Dermatitis
photo courtesy Jeffrey Edwards, MD

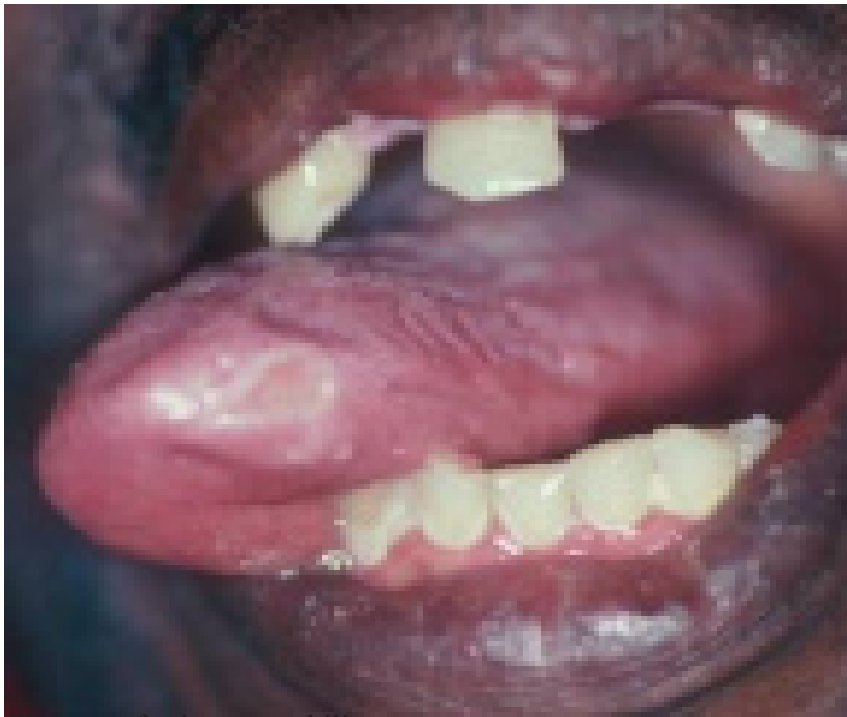Psoriasis
photo courtesy Jeffrey Edwards, MD





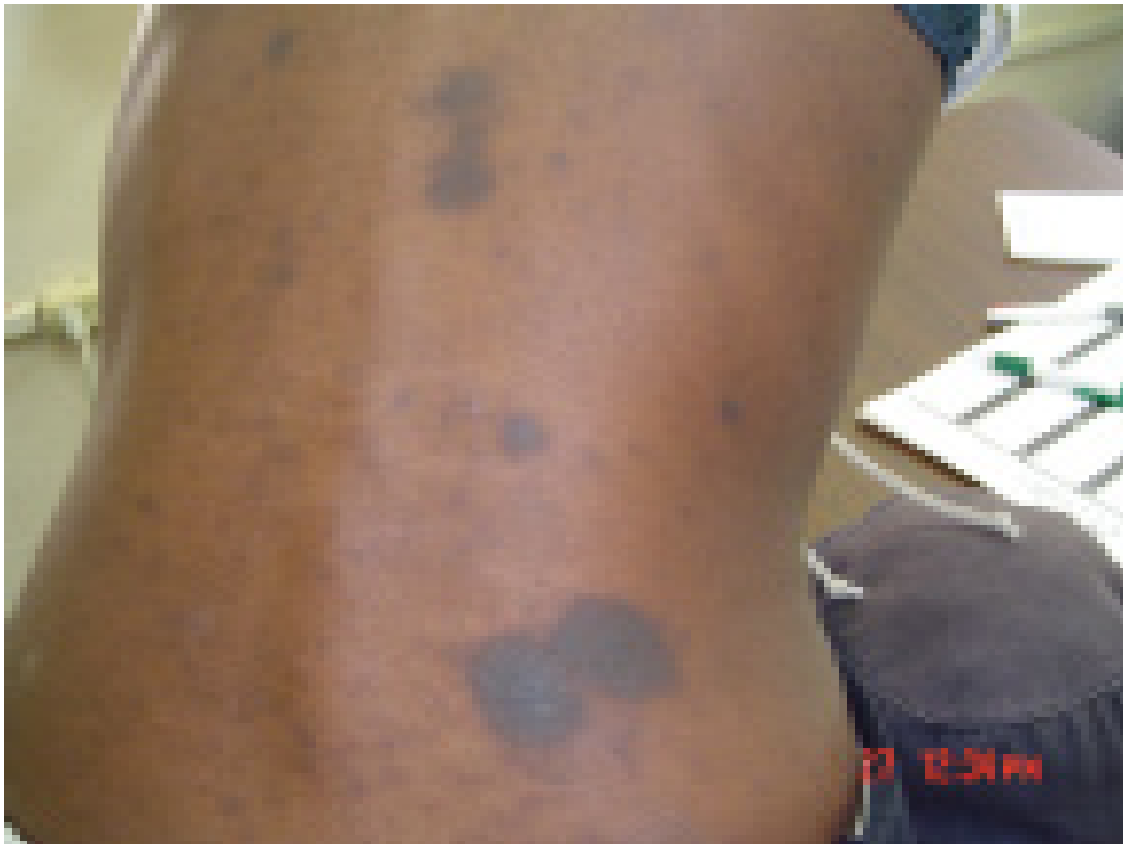Rash of secondary syphilis
photos courtesy Jeffrey Edwards, MD

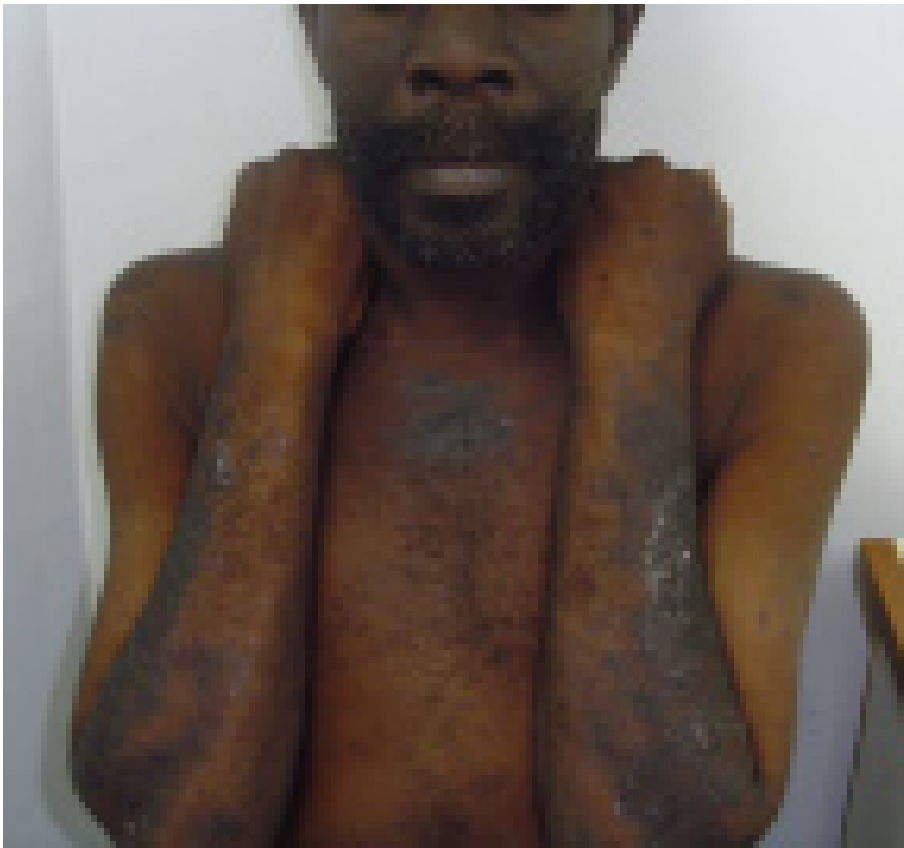



Chancre of primary syphilis
photo courtesy Mark Schubert, DDS

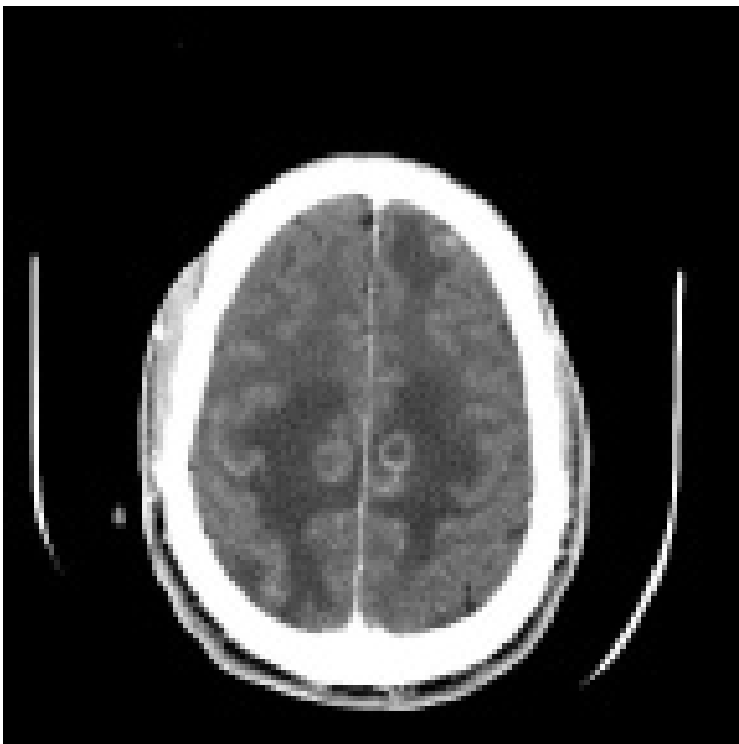
rash secondary to TMP-SMX (co-trimoxazole)
photo courtesy Jeffrey Edwards, MD

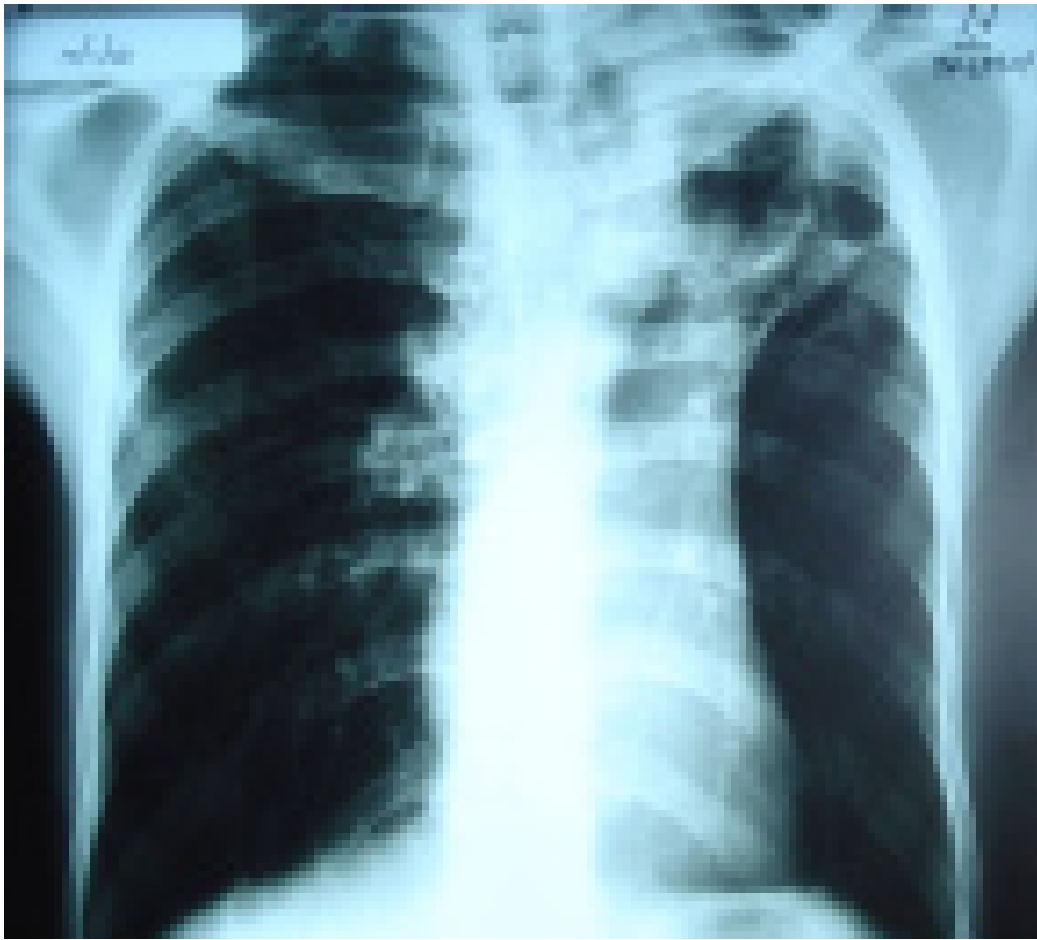




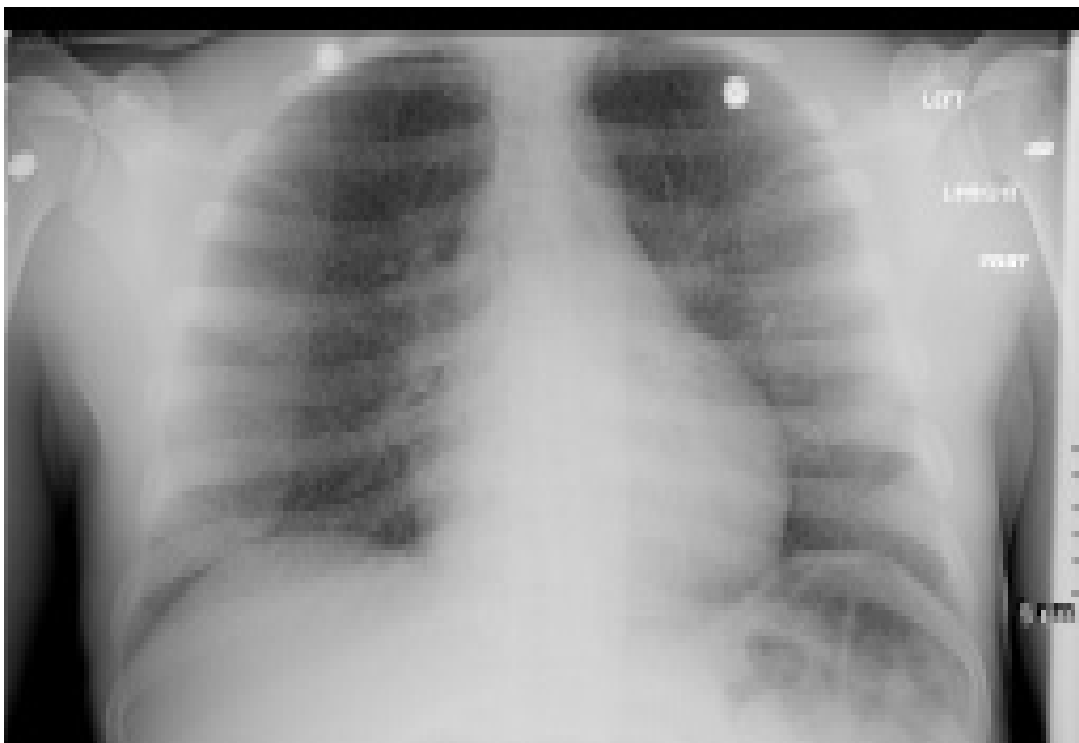
photosensitivity reaction to TMP-SMX (co-trimoxazole)
photo courtesy Jeffrey Edwards, MD

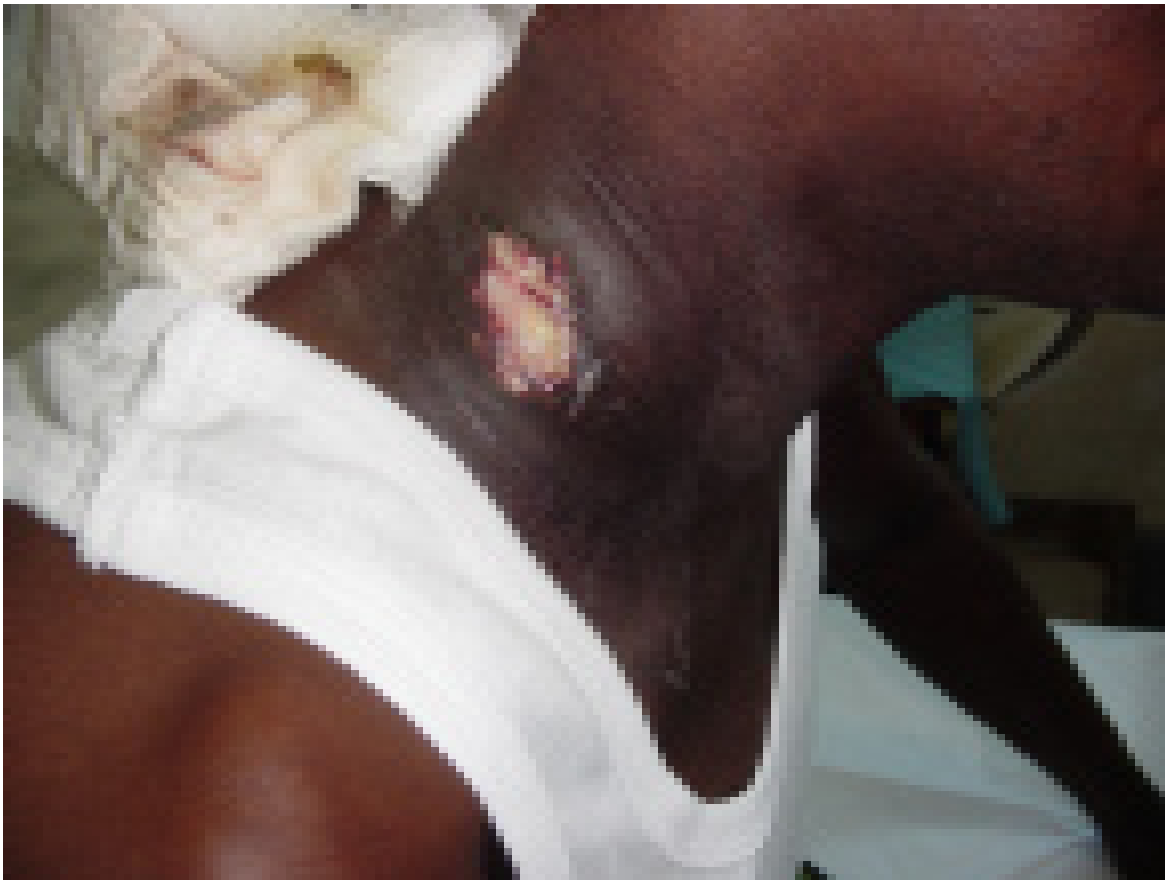Toxoplasmic encephalitis: ring-enhancing lesions on head CT with contrast
photo courtesy Christopher Behrens, MD





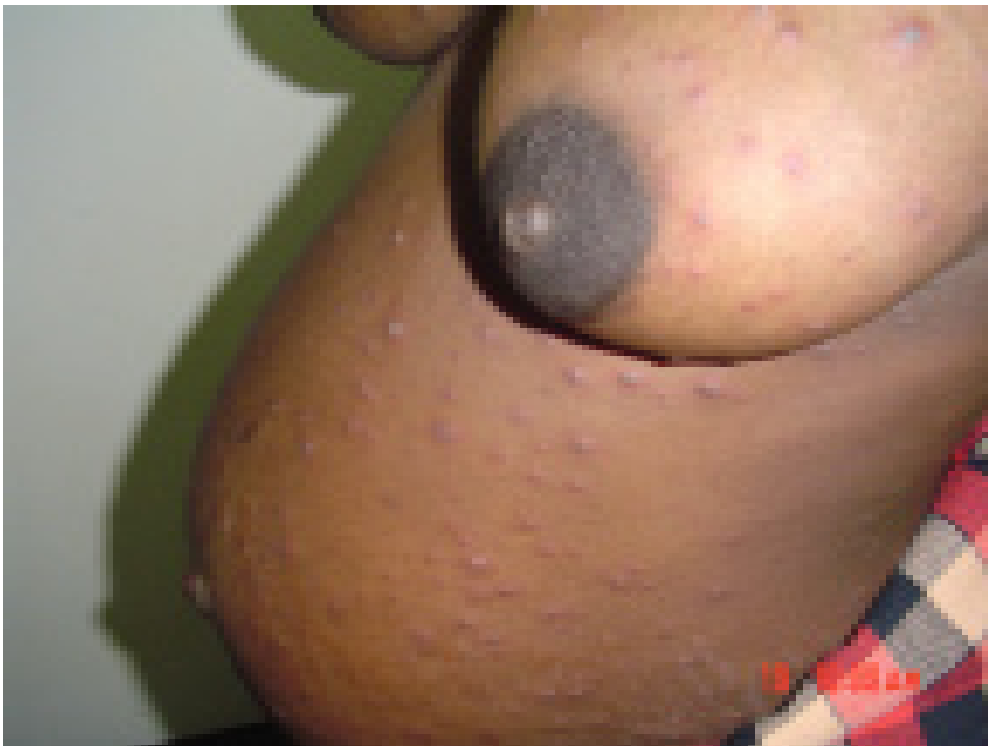Pulmonary tuberculosis: cavitary (above) and disseminated (below)
image s courtesy Jeffrey Edwards, MD

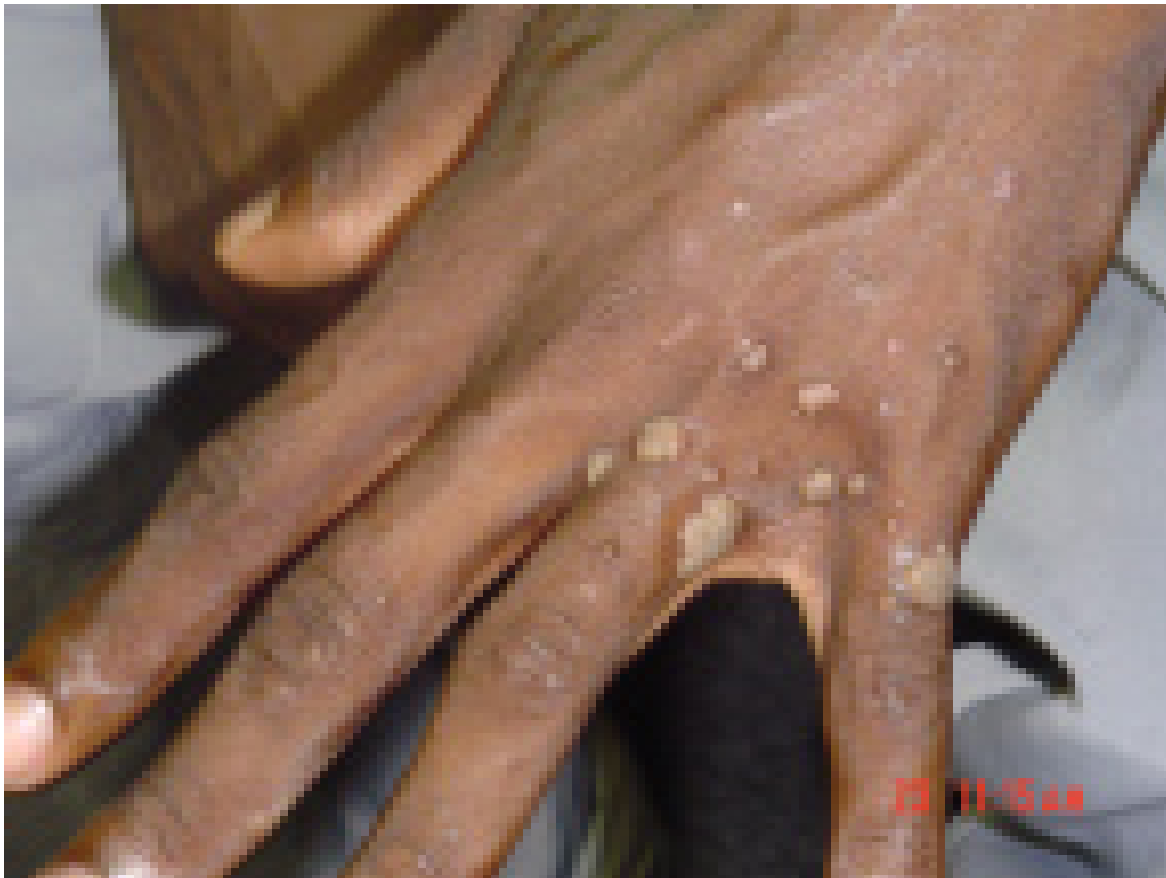



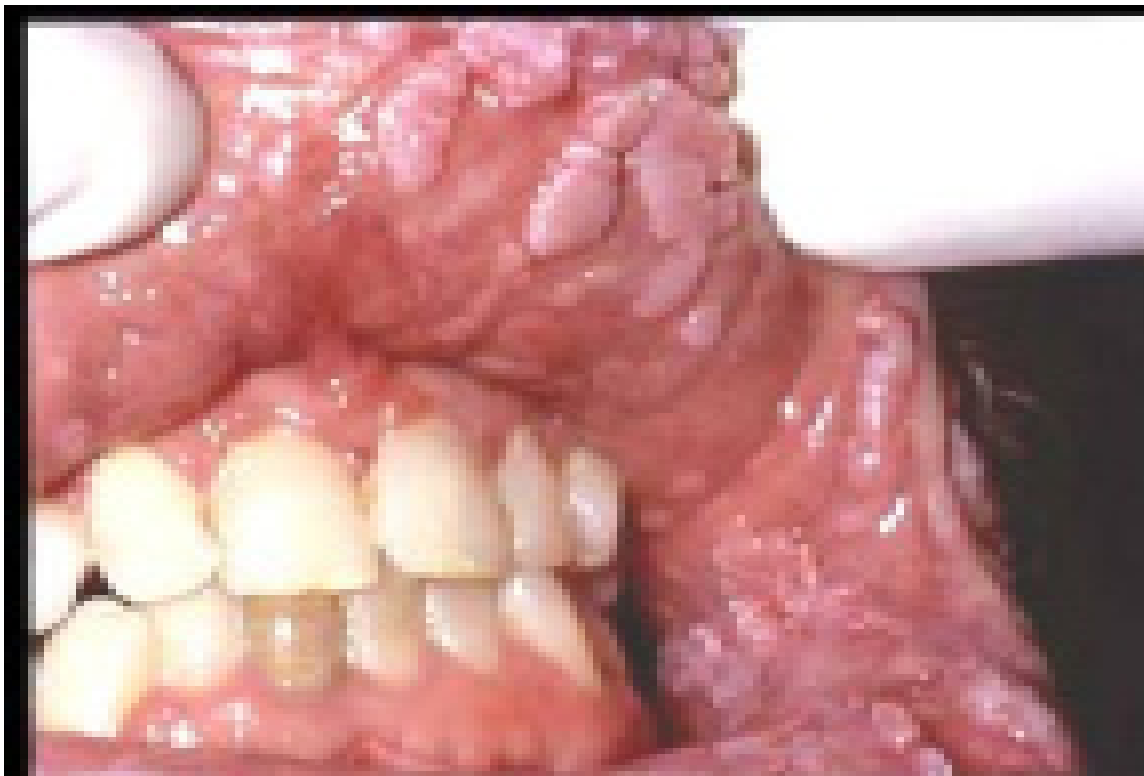Scrofula
photo courtesy Jeffrey Edwards, MD

Primary varicella during pregnancy
photo courtesy Jeffrey Edwards, MD





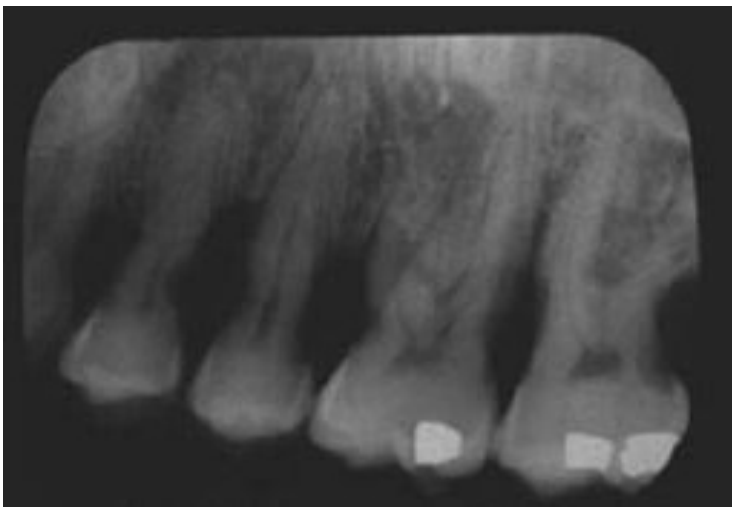
Plain warts of the hand and oral cavity
photos courtesy Jeffrey Edwards, MD (above) and Mark Schubert, DDS (below)

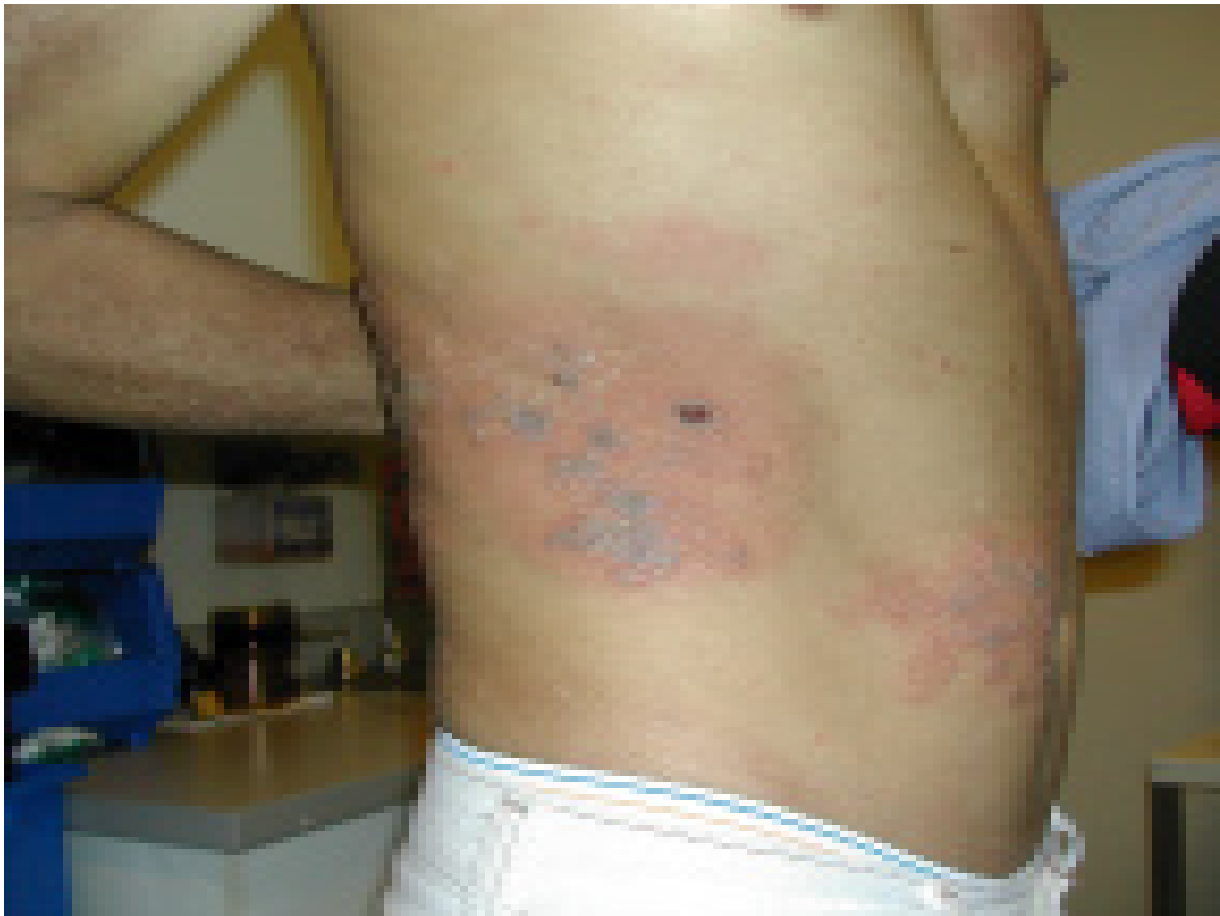



Severe penile warts
photo courtesy Jeffrey Edwards, MD

Dental caries secondary to HIV-induced xerostomia
image courtesy Mark Schubert, DDS





Zoster
photo courtesy Christopher Behrens, MD

Zoster involving the trigeminal nerve
photo courtesy Mark Schubert, DDS

